Innovations in Breast Cancer Surgery

V. Suzanne Klimberg, M.D.

Muriel Balsam Kohn Chair in

Breast Surgical Oncology

Professor of Surgery & Pathology

University of Arkansas for Medical Sciences

Director, Breast Cancer Program

Winthrop P. Rockefeller Cancer Institute

The greatest obstacle to discovery is not ignorance- it is the illusion of knowledge.

Daniel J. Boorstin

RFA: RadioFrequency Ablation

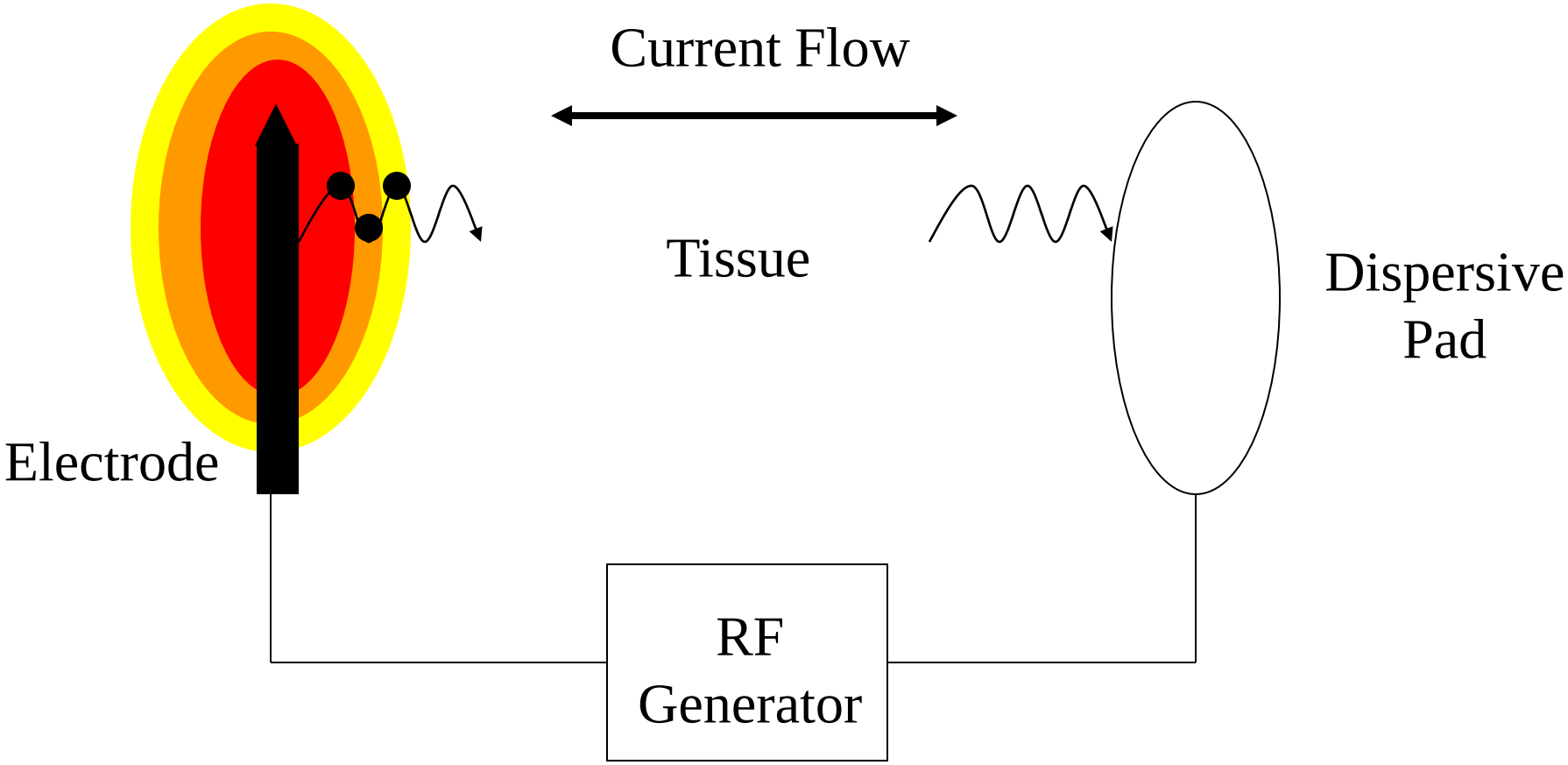

Radiofrequency Probes

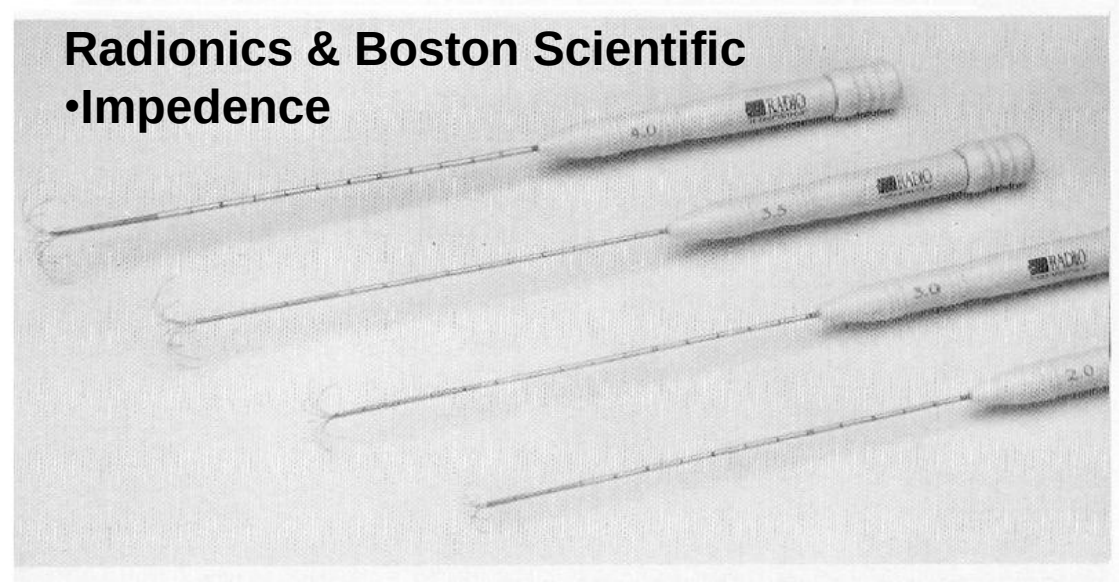

RFA of Breast Cancer. First Report of an Emerging Technology

Jeffrey SS, Birdwell RL Ikeda DM, et al

Arch Surg 1999;134:1064

- **Feasability Trial**
- **LABC (n=5)**
- **RFA → Mastectomy**
- **Ablation zones 0-8-1.8 cm in D**

RFA Ablation Trials

Trialc	Patients	n	Treatment	Outcome
Izzo et al, 2001 (pilot)	T1/2	26	US-guided RFA (margin of ≥ 5 mm)	Complete coagulative necrosis in 25/26 patients*
Fornage, 2004	Tumor ≤ 2 cm in diameter	21	RFA → surgery	Complete coagulative necrosis in 20 patients
Singletary, 2002	T1	30	Intraoperative RFA → excision	Complete ablation in 87% of patients
Burak et al, 2003	Tumor ≤ 2 cm in diameter	10	RFA → surgery (1-3 wk later)	No residual lesions detected on MRI in 8/9 patients†
Hayashi et al, 2003	Tumor ≤ 3 cm in diameter (T1)	22	RFA → surgery (1-2 wk later)	Complete coagulative necrosis in 19/22 patients
Noguchi et al, 2006	T1	10	RFA → surgery	No Viable Tumor

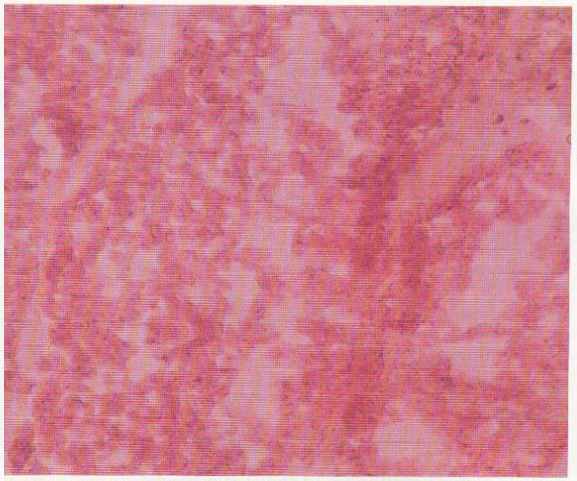

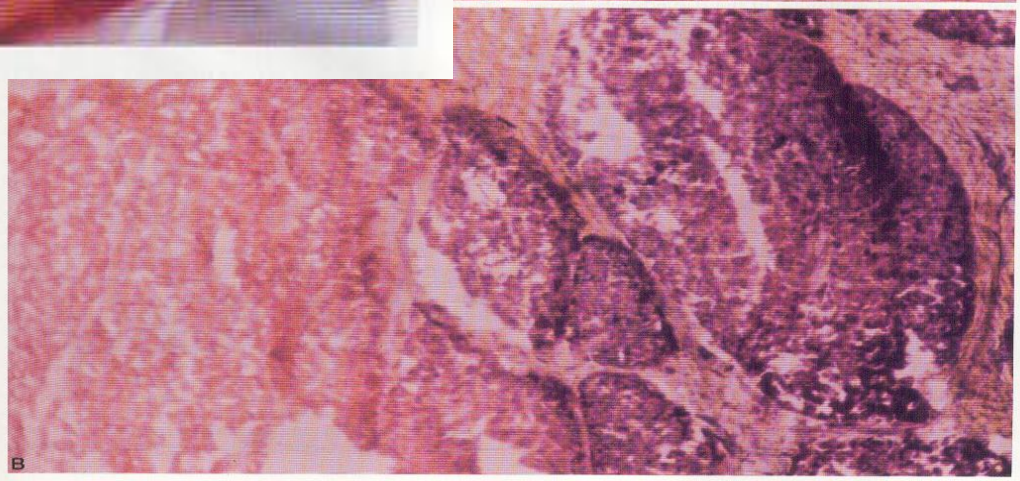

Izzo F, et al. Radiofrequency Ablation in Patients with Primary Breast Carcinoma *Cancer*, 92(8): 2036-2044, 2001

RFA Ablation Trials

Trialc	Patients	n	Treatment	Outcome
Izzo et al, 2001 (pilot)	T1/2	26	US-guided RFA (margin of ≥ 5 mm)	Complete coagulative necrosis in 25/26 patients*
Fornage, 2004	Tumor ≤ 2 cm in diameter	21	RFA → surgery	Complete coagulative necrosis in 20 patients
Singletary, 2002	T1	30	Intraoperative RFA → excision	Complete ablation in 87% of patients
Burak et al, 2003	Tumor ≤ 2 cm in diameter	10	RFA → surgery (1-3 wk later)	No residual lesions detected on MRI in 8/9 patients†
Hayashi et al, 2003	Tumor ≤ 3 cm in diameter (T1)	22	RFA → surgery (1-2 wk later)	Complete coagulative necrosis in 19/22 patients
Noguchi et al, 2006	T1	10	RFA → surgery	No Viable Tumor

RFA Ablation Trials

Trialc	Patients	n	Treatment	Outcome
Izzo et al, 2001 (pilot)	T1/2	26	US-guided RFA (margin of ≥ 5 mm)	Complete coagulative necrosis in 25/26 patients*
Fornage, 2004	Tumor ≤ 2 cm in diameter	21	RFA → surgery	Complete coagulative necrosis in 20 patients
Singletary, 2002	T1	30	Intraoperative RFA → excision	Complete ablation in 87% of patients
Burak et al, 2003	Tumor ≤ 2 cm in diameter	10	RFA → surgery (1-3 wk later)	No residual lesions detected on MRI in 8/9 patients†
Hayashi et al, 2003	Tumor ≤ 3 cm in diameter (T1)	22	RFA → surgery (1-2 wk later)	Complete coagulative necrosis in 19/22 patients
Noguchi et al, 2006	T1	10	RFA → surgery	No Viable Tumor

RFA for Minimally Invasive Treatment of Breast Carcinoma. A Pilot Study in Elderly Inoperable Patients

Susini T, Jacopo N, Olivieri S, Livi L, Bianchi S, Mangialovori G, Branconi F, Scarselli G

Gynecologic Oncology 104(2007)304-310

- 3 Pts (78-86yo) With <2cm BC
- Perc RFA with Margin
- F/U 18 months – Ø LR
- US, Mam, MRI, Core Bx

Benefits of Percutaneous Ablation

- Minimize Morbidity
- Minimize Side-effects
- Reduce Costs

Problems with Percutaneous Ablation

- Incomplete Pathology
- Mass Effect
- Lack of Assessment of Complete Ablation/Imaging
- Loss of Tumor Banking Tissue
- Limitations of Extent of Ablation
- Expertise Required

PeRFA: Percutaneous Excision & Ablation

STEREO Vs US-GUIDED BX

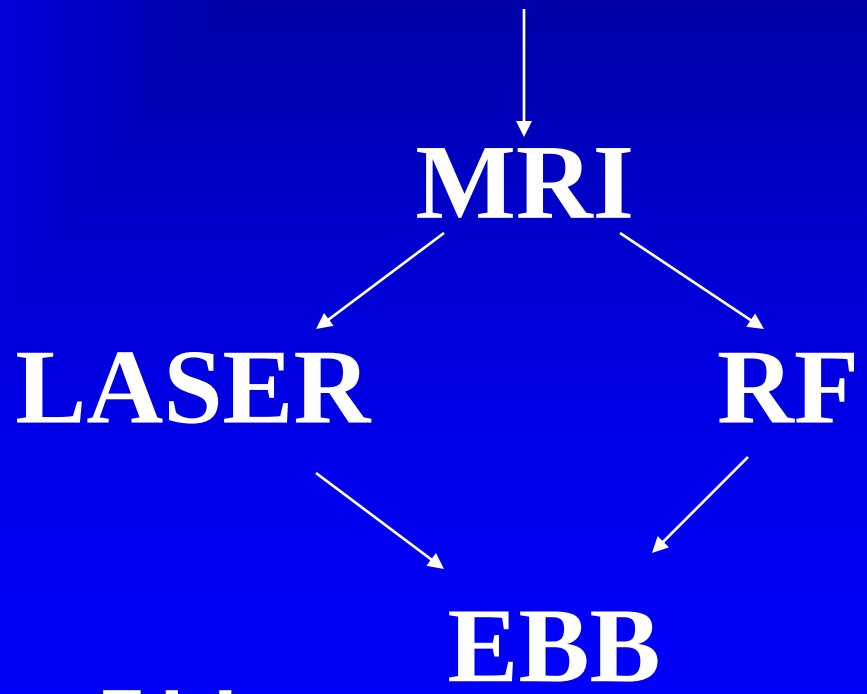

NCI Sponser Trial
Ethicon/RITA

Disease Extension

- Holland R, et al. Cancer:56:979;1985
  - Gross Total Excision
- Imamura H, et al BCRT 62:177;2000

  <64 y.o. - 8.32 mm

  ≥64 y.o. - 5.28 mm
- Ohtake T, et al.
  - Cancer 76:32;1995

  >50 y.o. - 6.7 – 7.7 mm
- Vicini T, et al. Reexcision - 90% <1 cm

T1<1cm

Breast Cancer Resection and Volume



Breast Cancer Resection and Volume

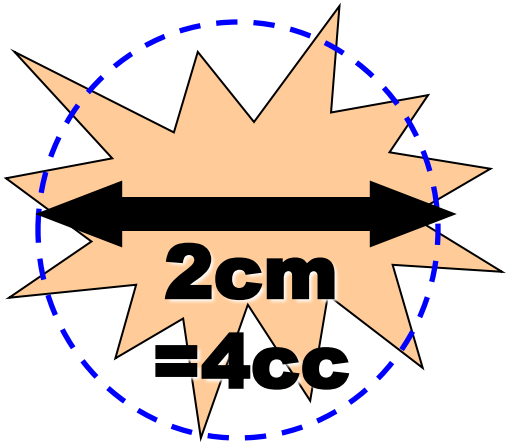

Breast Cancer Resection and Volume

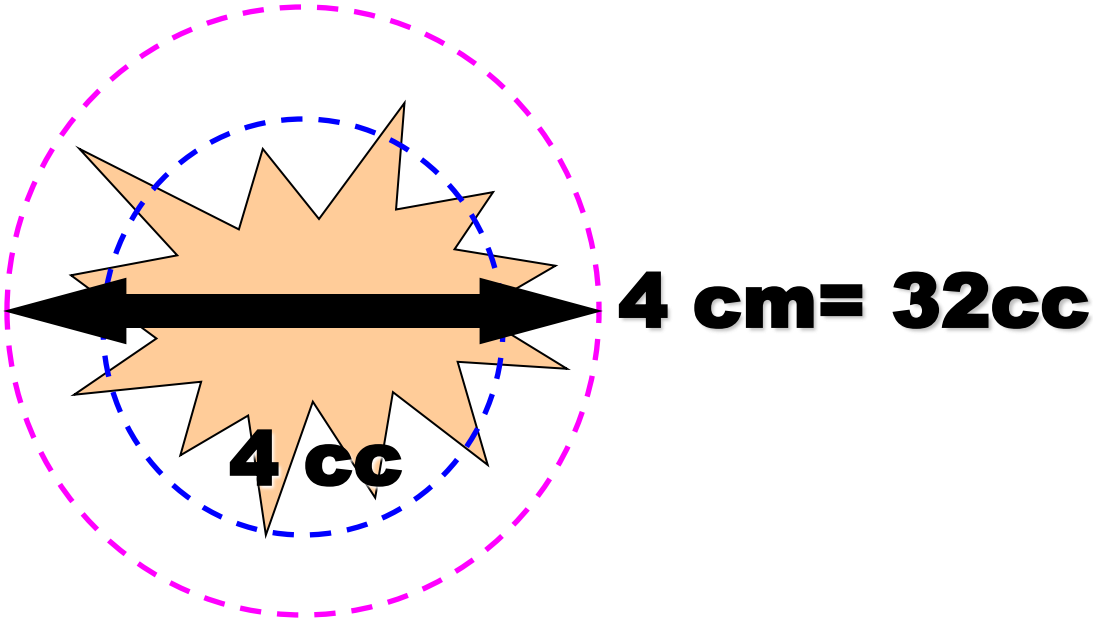

Breast Cancer Resection and Volume

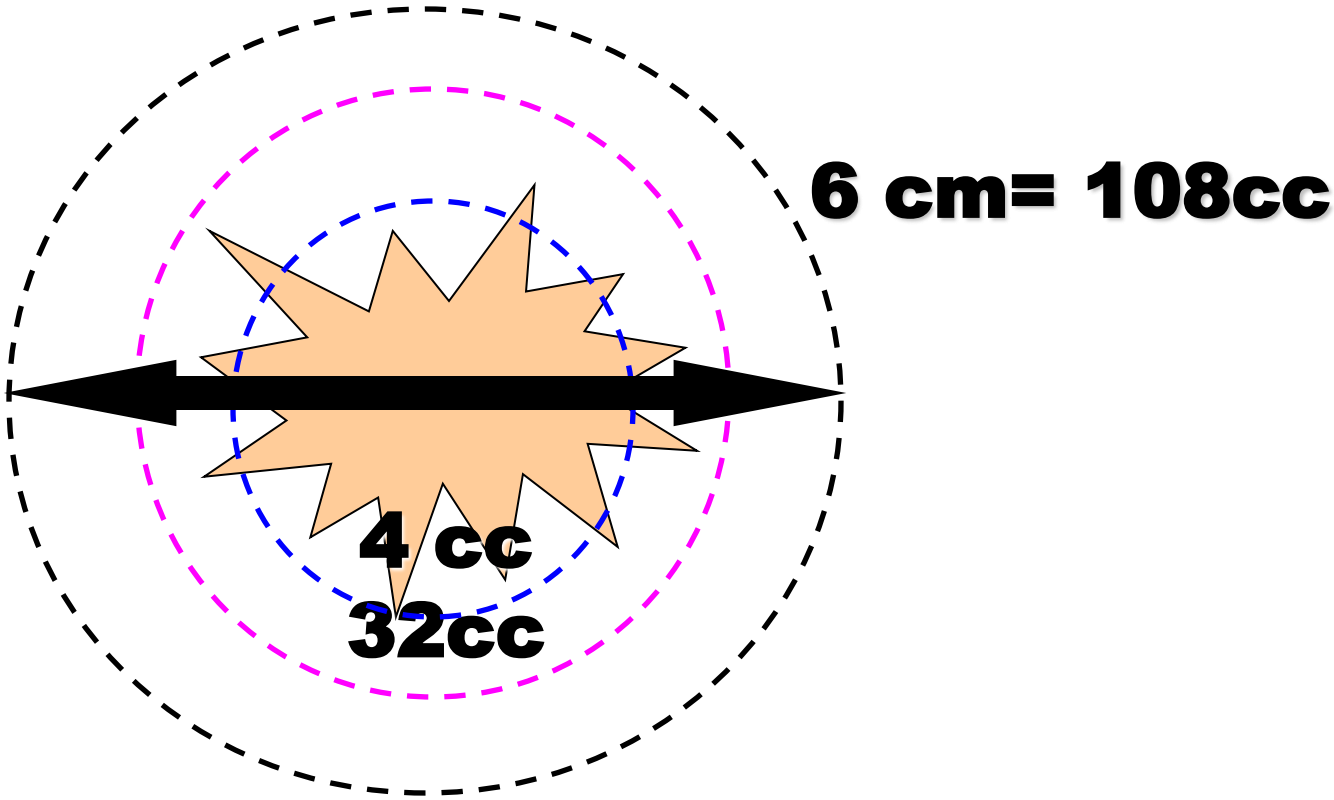

- Average Resection Size

Breast Cancer Resection and Volume

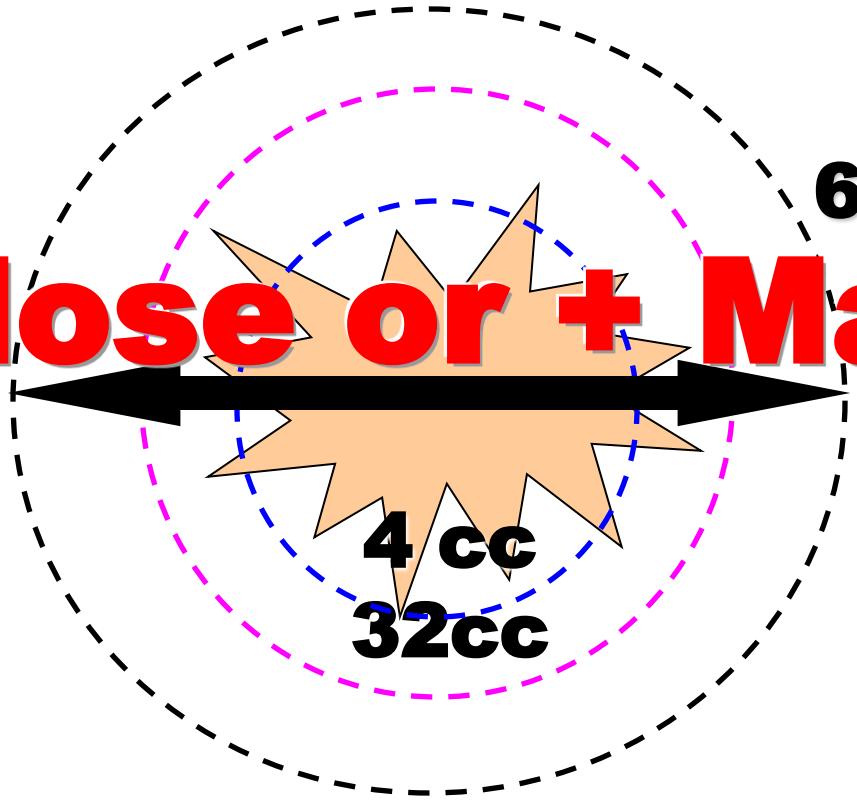

4o% Close or + Margins

- **Average Resection Size**

Breast Cancer Resection and Volume

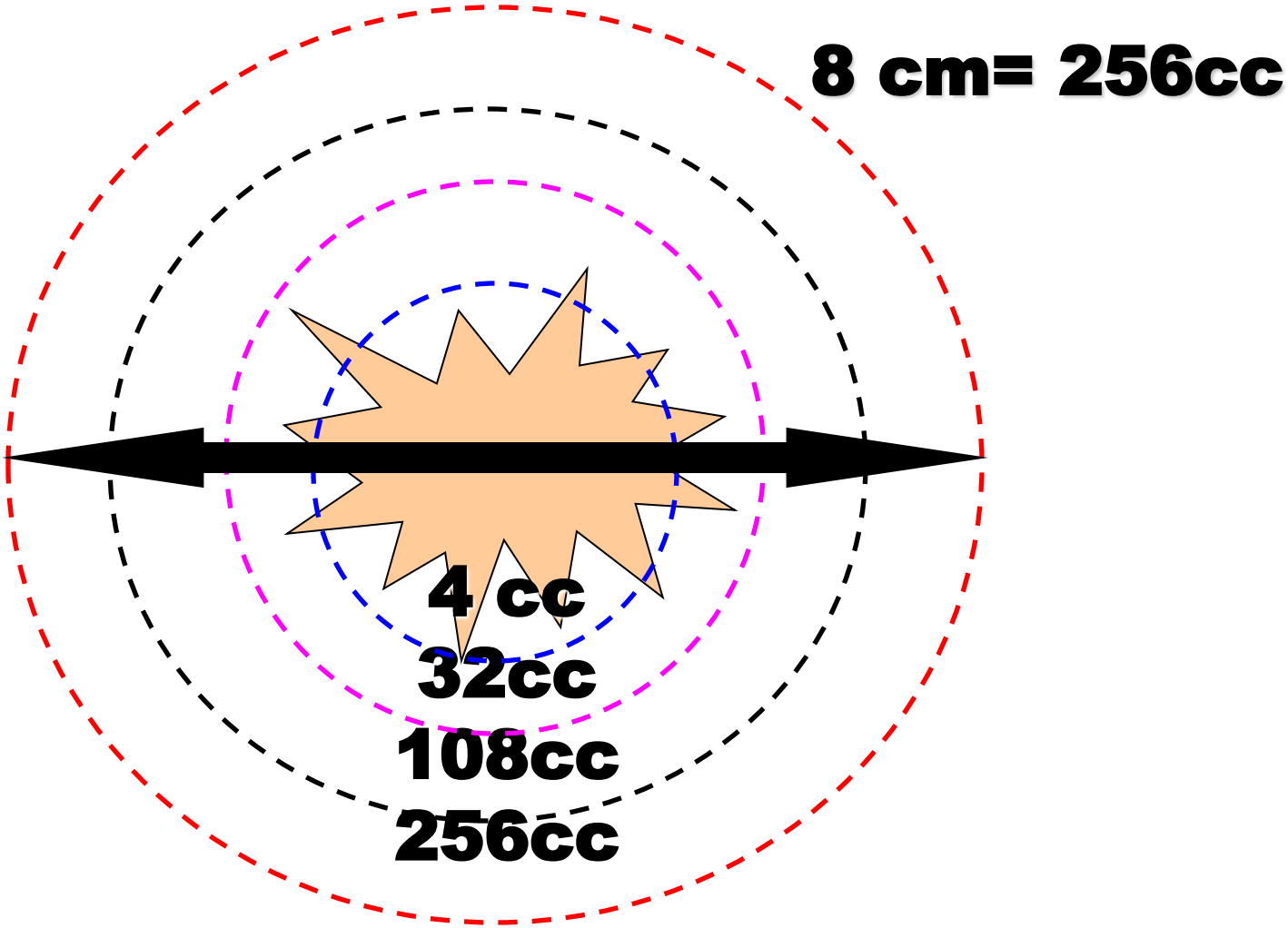

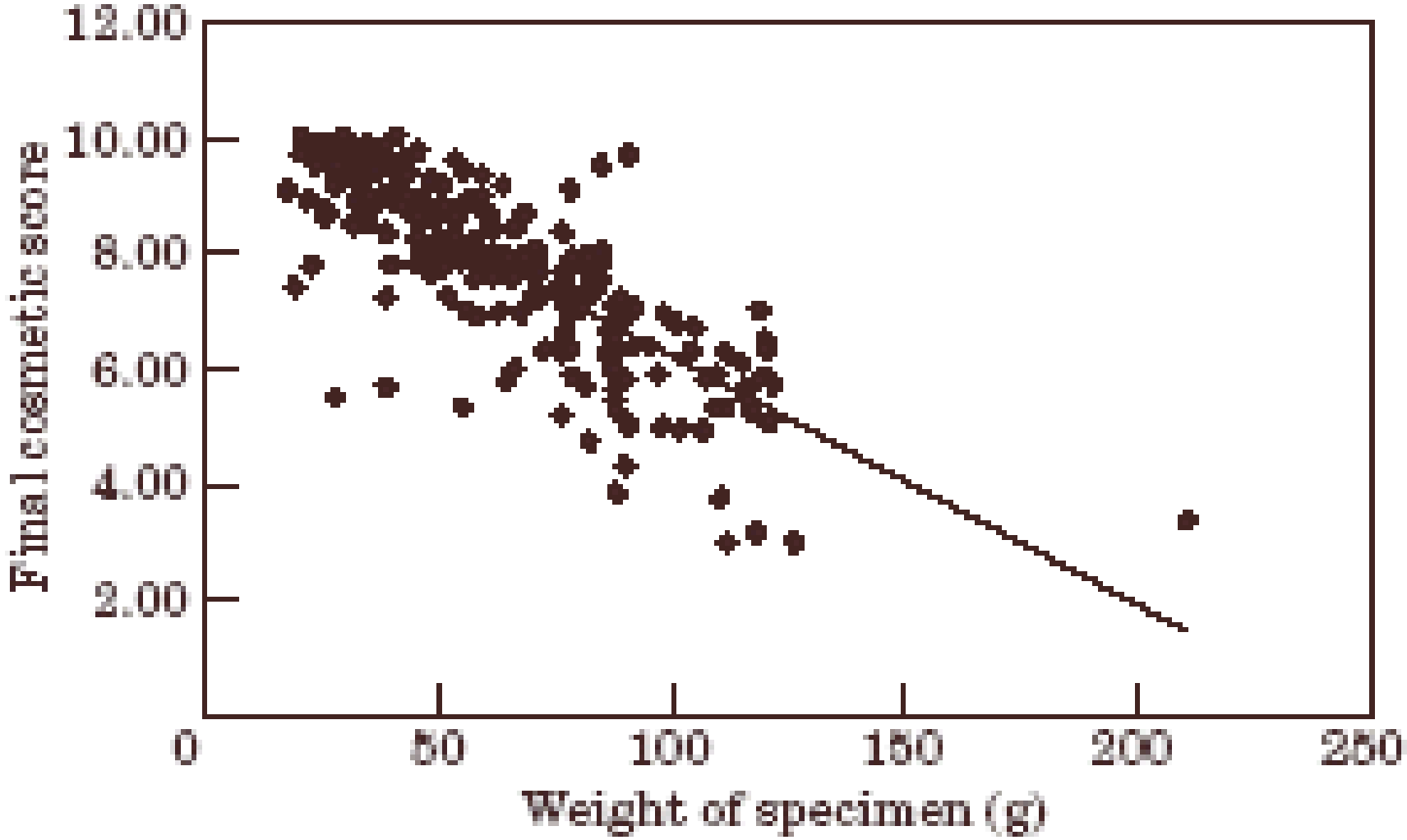

Fig. 1. The relationship between the weight of the specimen and cosmetic outcome.

Al-Chazal et al

Minimally Invasive EBB

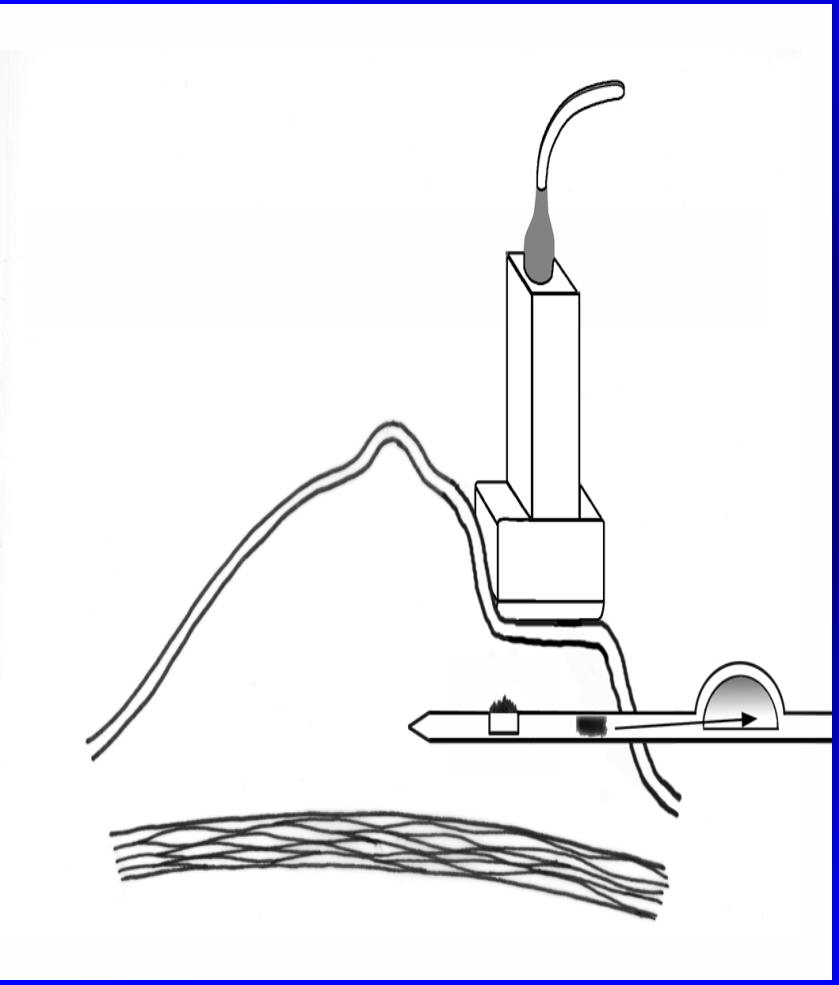

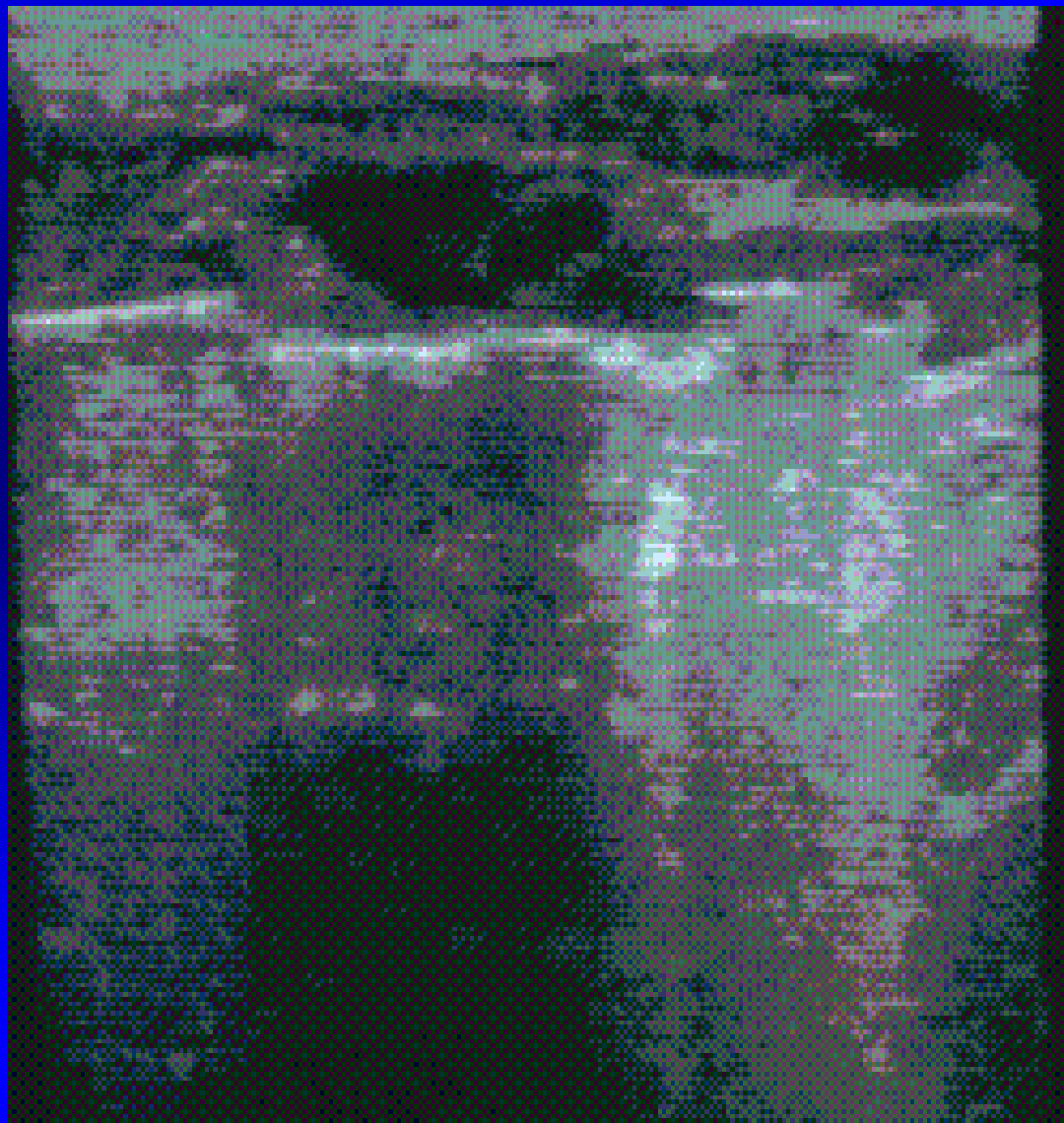

US-Directed Margin Ablation

- RF Vs Laser to ablate a 1 cm margin

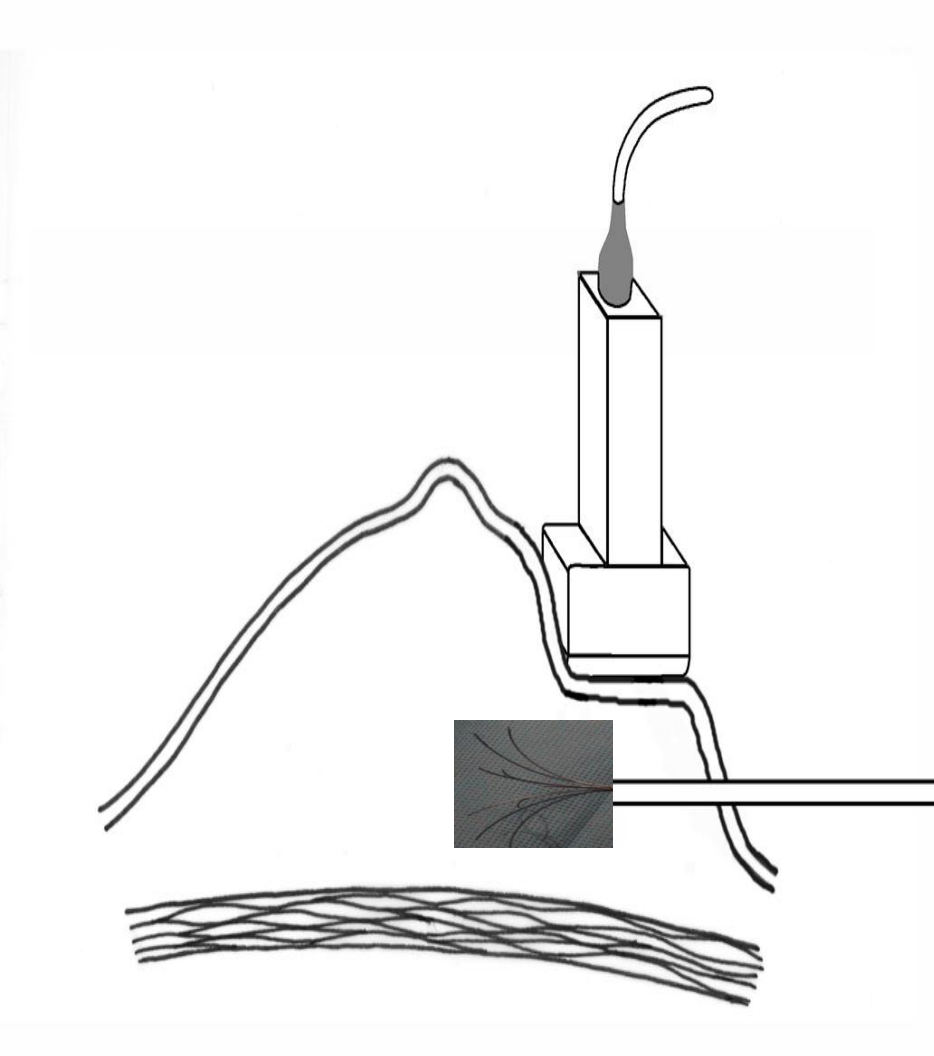

0 mm
UAMS ONE DAY SURGERY
HUG



Real-Time Visualization of Extent of PeRFA

Post Ablation Lumpectomy

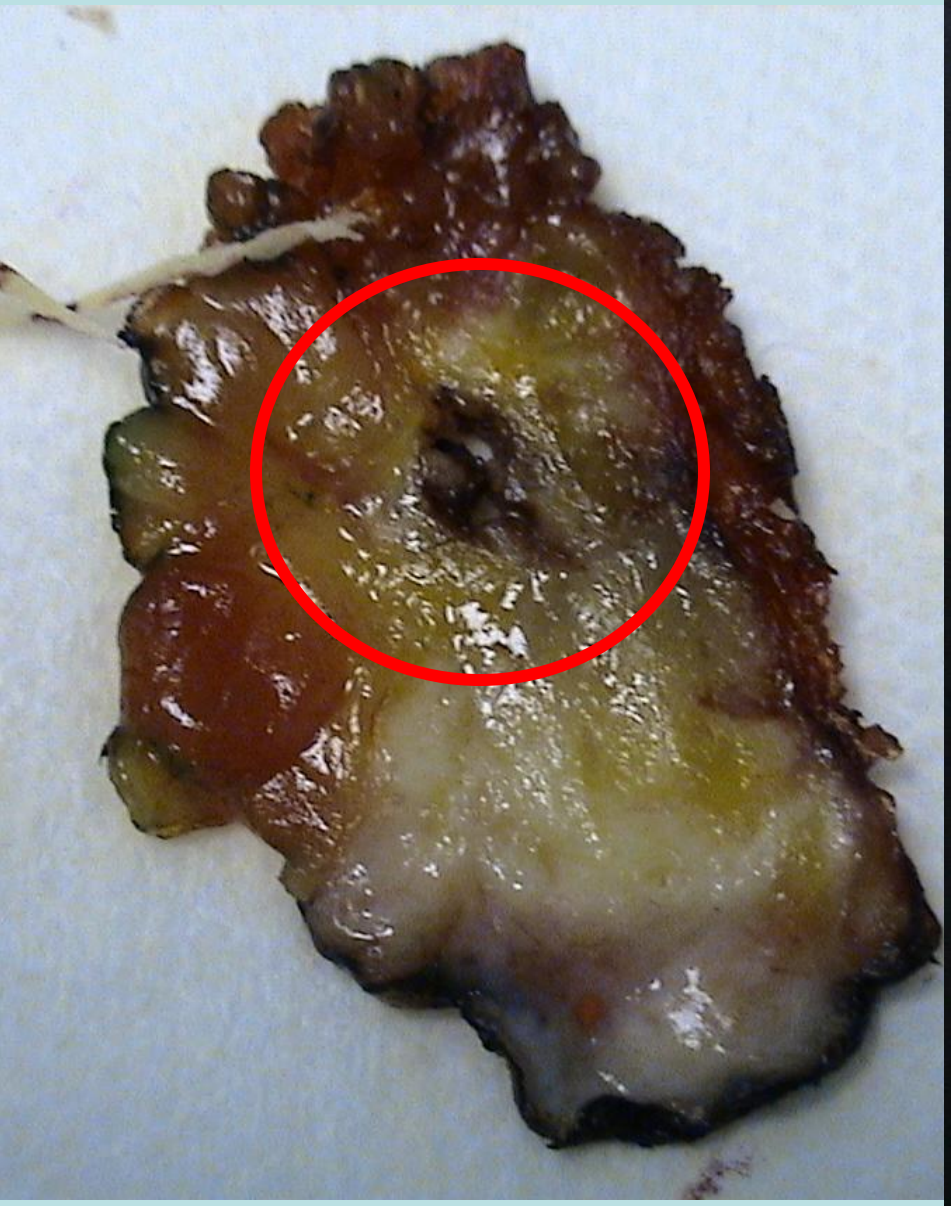

Lumpectomy Site Ablation

Percutaneous Exision & Ablation

- 21 Patients
- Laser Arm Stopped
- 14 patients in eRFA arm
  - 100% Complete Ablation
  - 7 with Dead Tumor Present at Excision Site

Percutaneous Excision & Ablation *Advantages*

- Complete Pathologic Information
- Ablate Margins instead of Excise
- Doppler Can Image Process
- Could obviate need for Open Surgery & XRT

Percutaneous Excision & Ablation *Disadvantages*

- Required Expertise
- Size Limited Group
  - ≤1.5 cm
  - ≥1.0 cm from Skin

eRFA

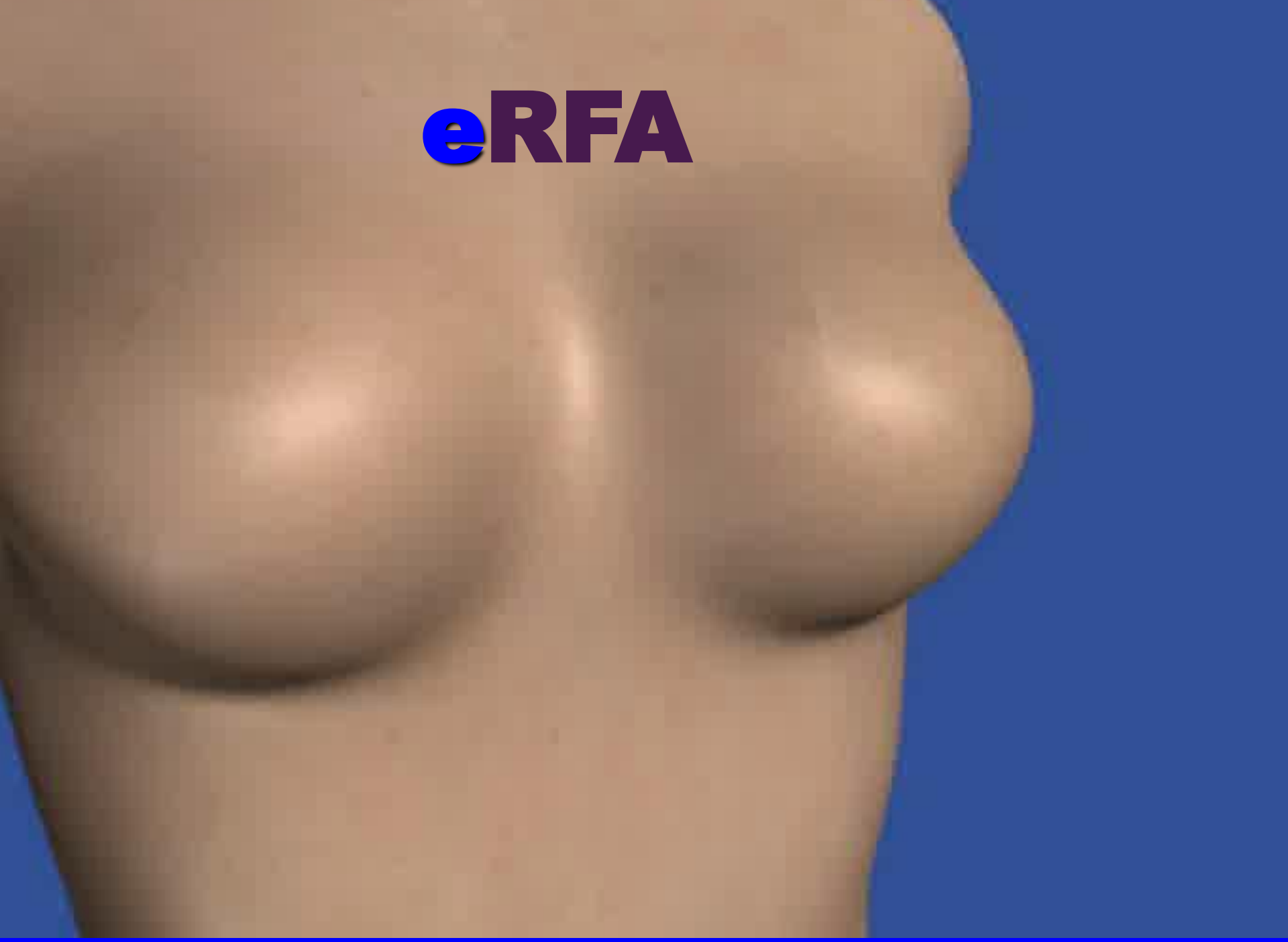

eRFA More than DoublesTreated Volume of Tissue Without Further Resection

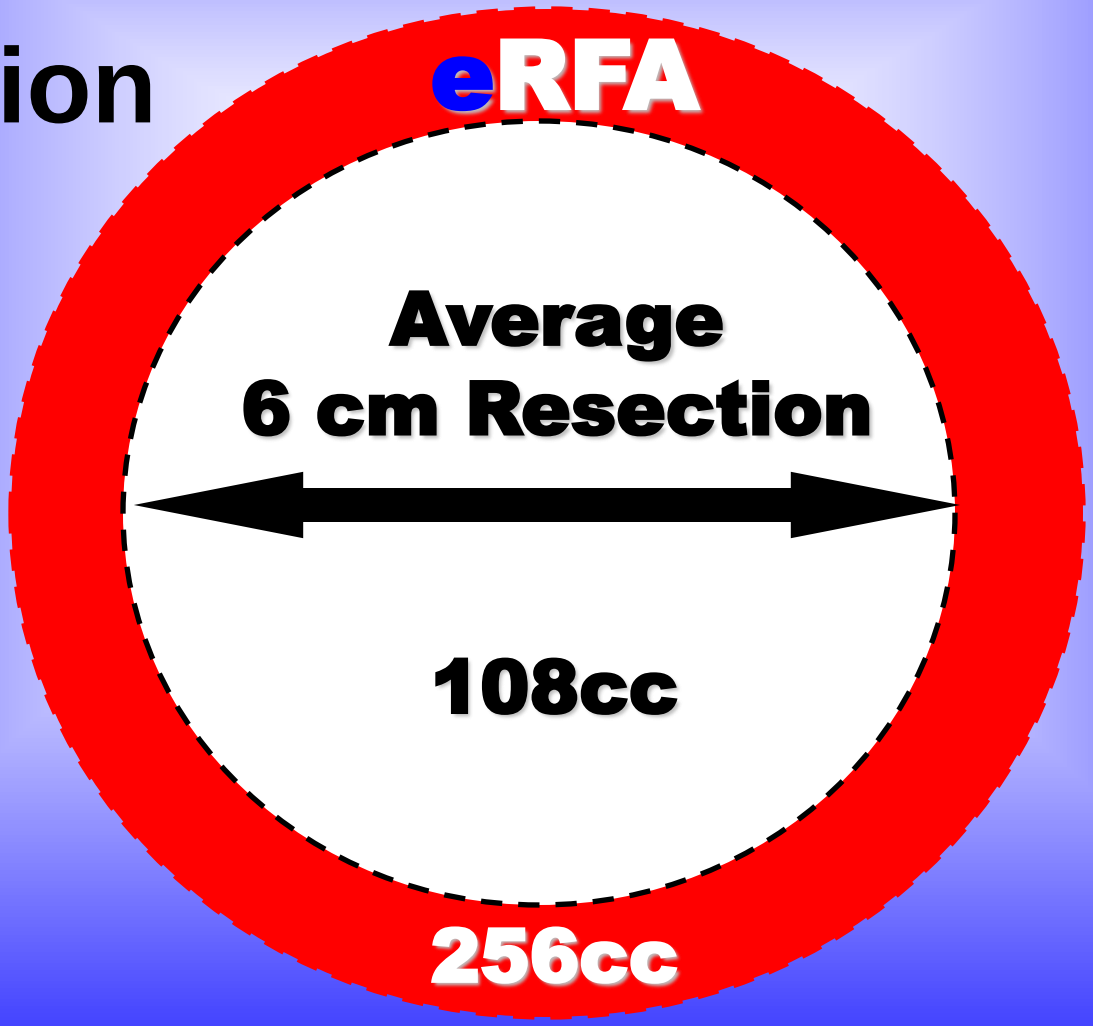

PeRFA

May Represent a Paradigm Shift in the Treatment of Breast Cancer

Breast Team™ Acknowledgements

- Cristiano Boneti, MD
- Isabel Rubio, MD
- Lynette Smith, MD
- Ronda Henry-Tillman, MD
- Julie Kepple, MD
- Anita Johnson, MD
- Steve Harms, MD
- Kent Westbrook, MD
- Maureen Colvert, BS,OCN
- Laura Adkins, MS
- Jim Coad, MD
- Gal Shafirstein, PhD
- Milton Waner, MD
- Scott Ferguson
- Valentina Todorova, PhD
- Rak Layeeque, MD
- Aaron Margulies, MD
- Soheila Korourian, MD
- Shiela Mumford
- Roberta Clark, BS

Conservative Breast Surgery

- >150,000 Lumpectomies per Yr
- Conserve the Breast by Removing Cancer with a Tumor-free Zone or Margin.
  - Conservative Breast Surgery
  - Lumpectomy
  - Segmentectomy
  - Partial Mastectomy

    Vs
  - Excisional Breast Biopsy used for Benign

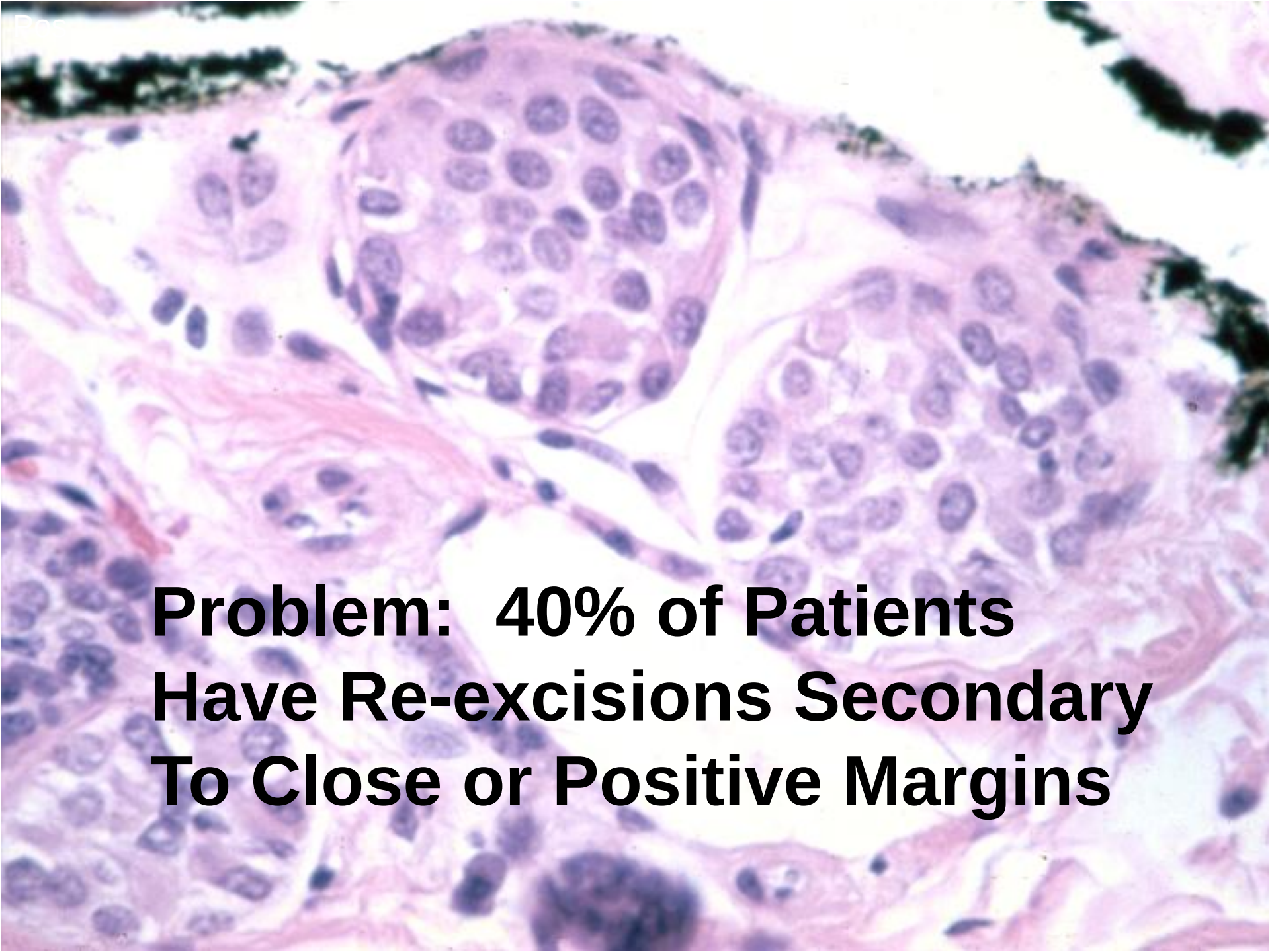

Problem: 40% of Patients Have Re-excisions Secondary To Close or Positive Margins

Needle Localization Breast Biopsy ⬆ Risk of + Margins

- Primary means of targeting mammographic abnormalities
- 40 to 75% + Margins

Margin Negativity is the Only Prognostic Factor that Surgeons Can Affect

Definition of a Negative Margin

- One Cell to One Centimeter
- ⬆ Recurrence Rate < 3 mm -Freedman et al Int J Rad Onc Biol Phys 1999. 15;44(5):1005
- LRR after CBS – 7%➡14%➡27% for Extensive, Focal or (-) Margins – Park et al JCO 2000;18(8):1668-75

Problems with Pathology

- Intraoperative Pathology Not Accurate for Depth of Margins
- Permanent Pathology only an Estimation of What is There

  - Only Test ~1/1000 of Margin

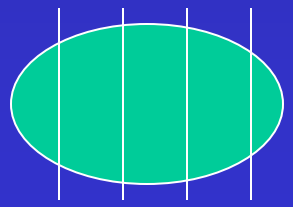

Carter et al

Surgical Excision

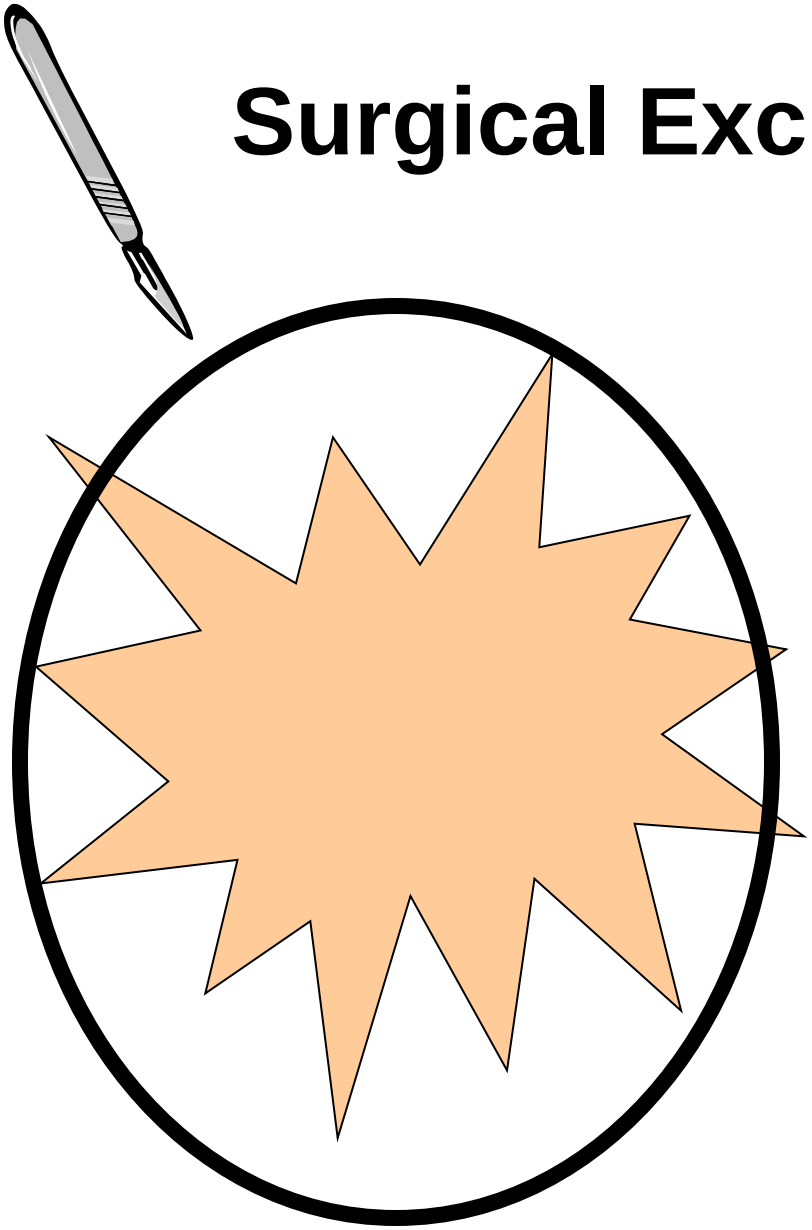

Excised Lumpectomy Specimen

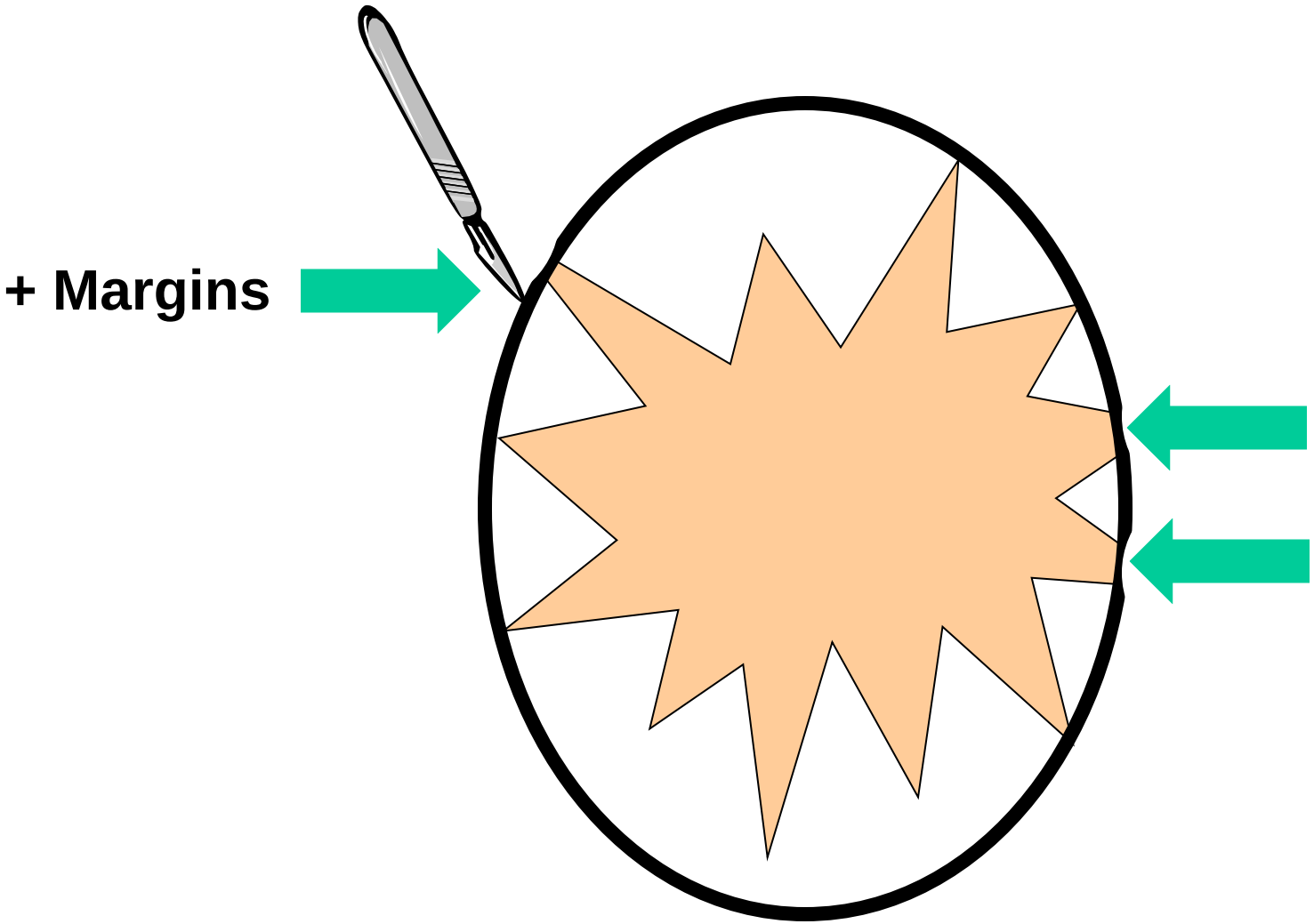

- Positive margins

Modern Day Pathology Only Estimates The Surgical Margin

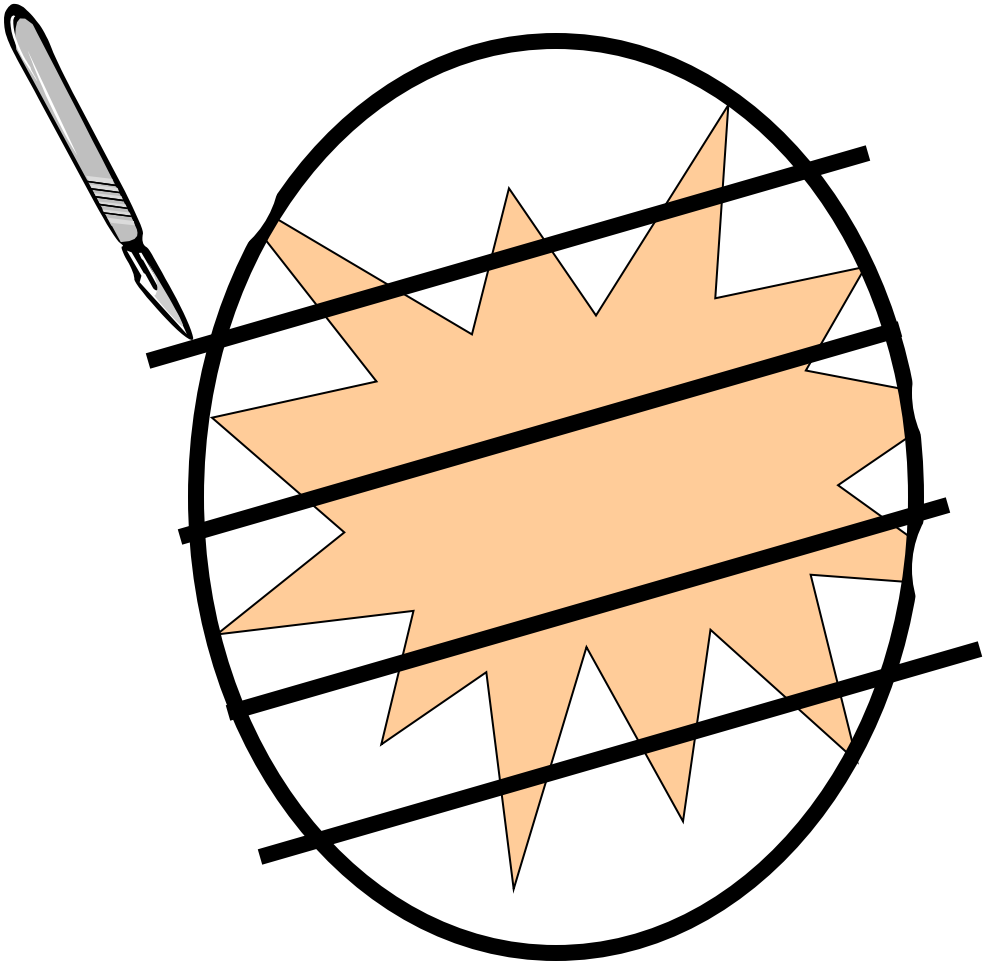

- Carter Estimated Needed 3,000 Sections Through a 2cm Tumor to Accurately Assess the Margins
- Pathology Assesses ~ 1/1000 of The Margin

Whole Mount of Invasive Breast Cancer

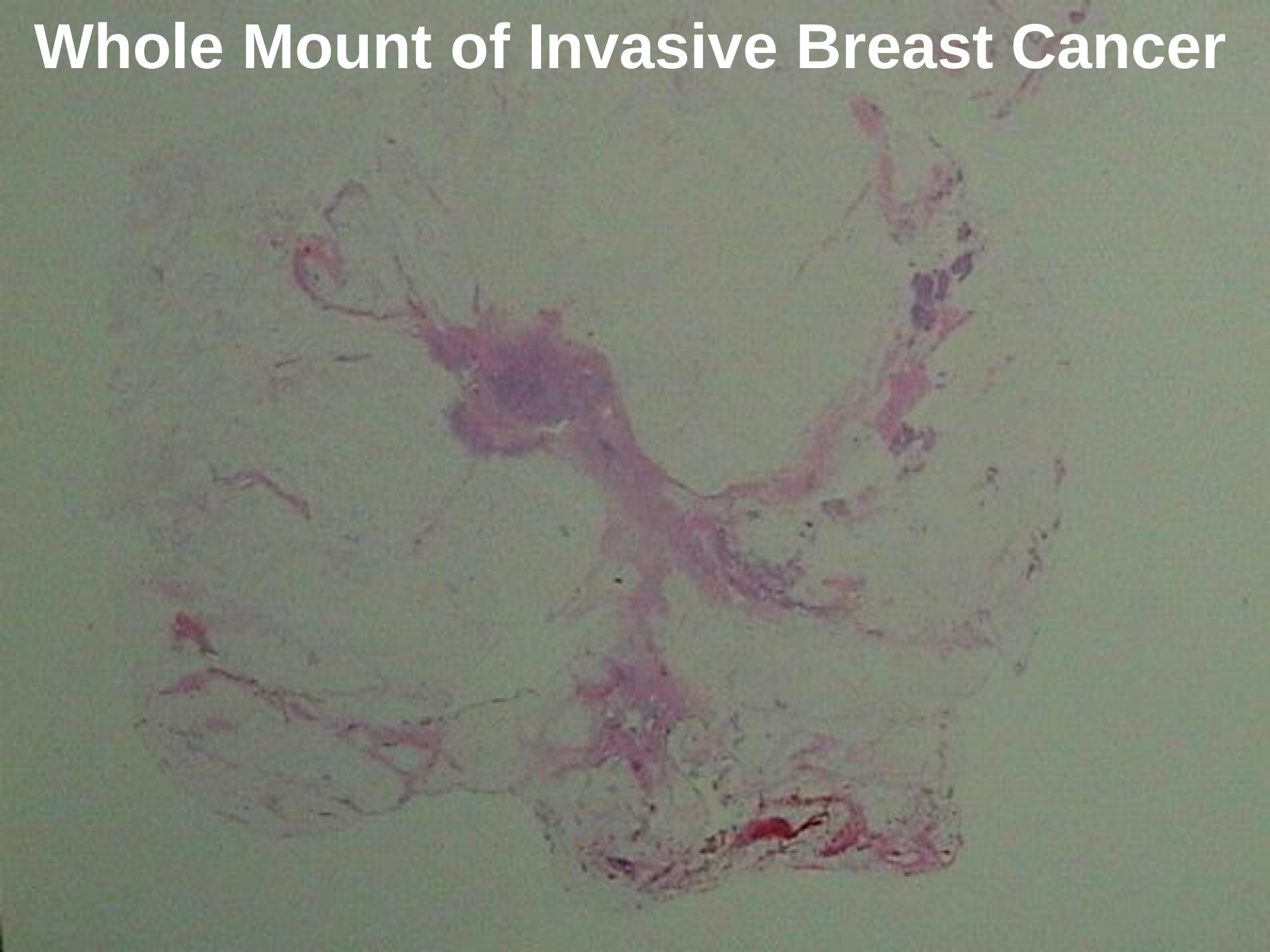

Path Sectioning Can Miss + Margins

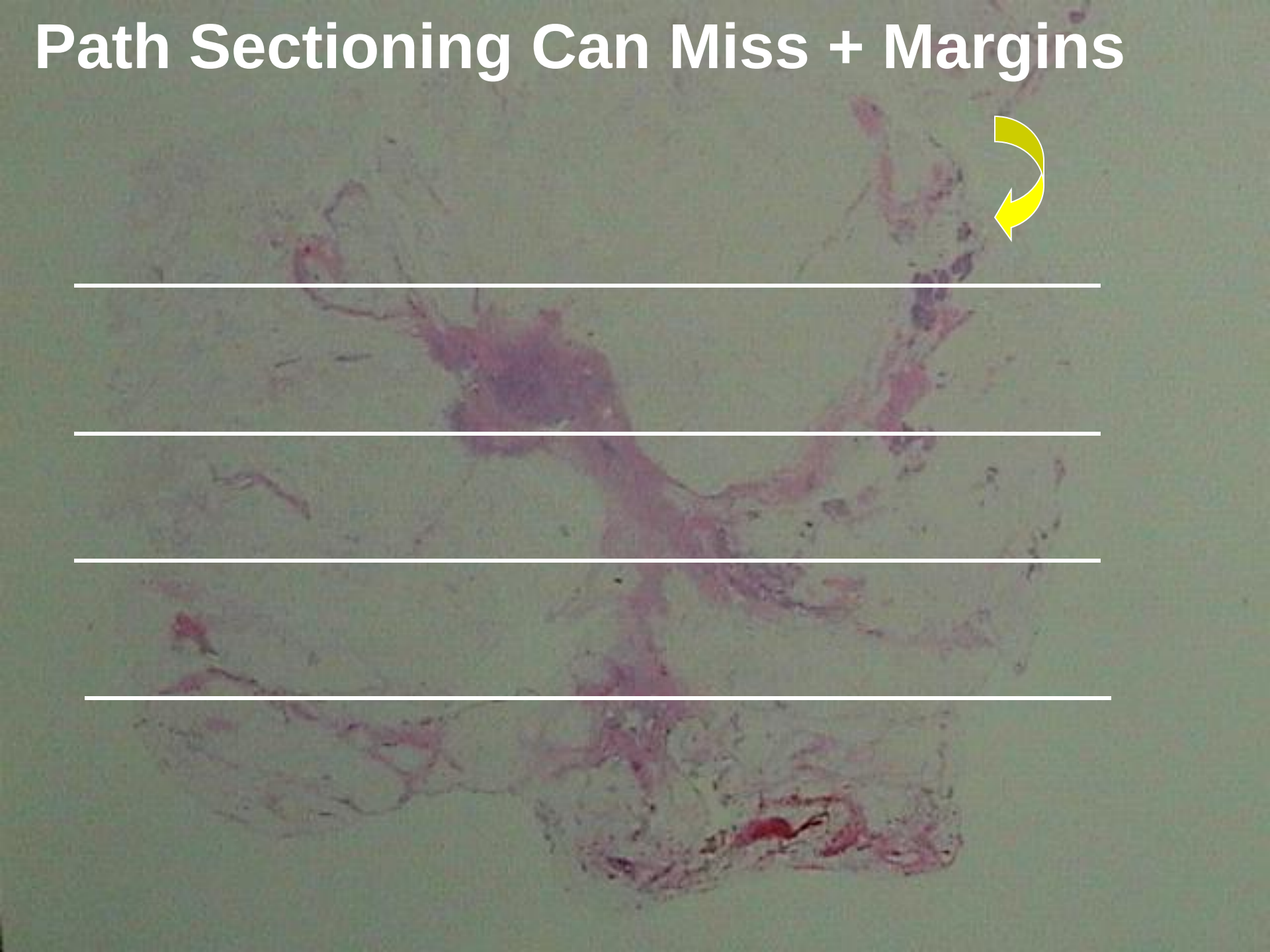

Residual Cancer Found After Re-excision

- Negative (>2mm) – 12-26%
- Close (<2mm) - 7-32%
- Focally Positive- 28%
- Positive- 50-75%

Smitt, Cancer 1995

Residual Disease on Re-Excision by Initial Resection Margin Width

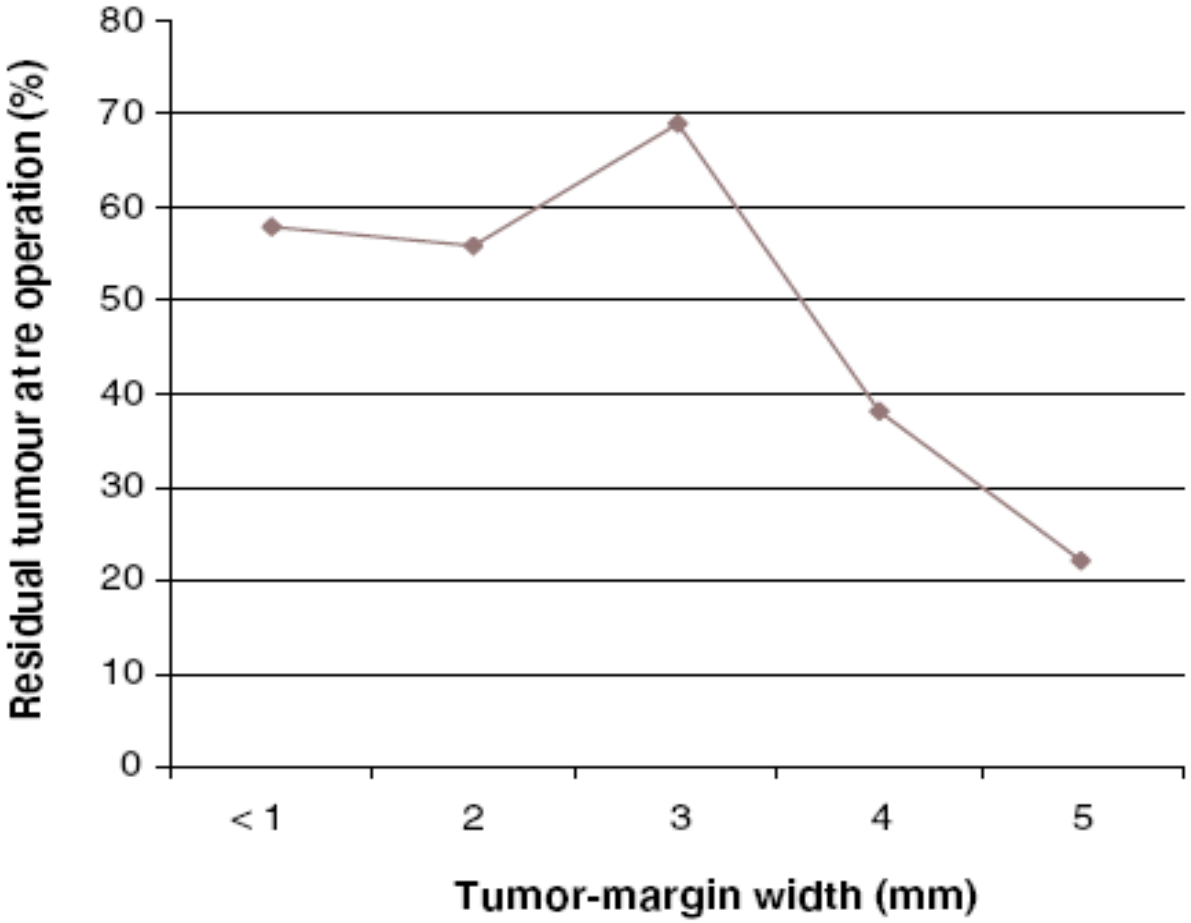

FIG. 1. Tumor-margin distance related to the presence of residual disease found at reoperation. $P = .03$; χ^2 test for trend.

Dillon et al Ann Surg Onc 2006

Residual Disease on Re-Excision by Initial Resection Margin Width

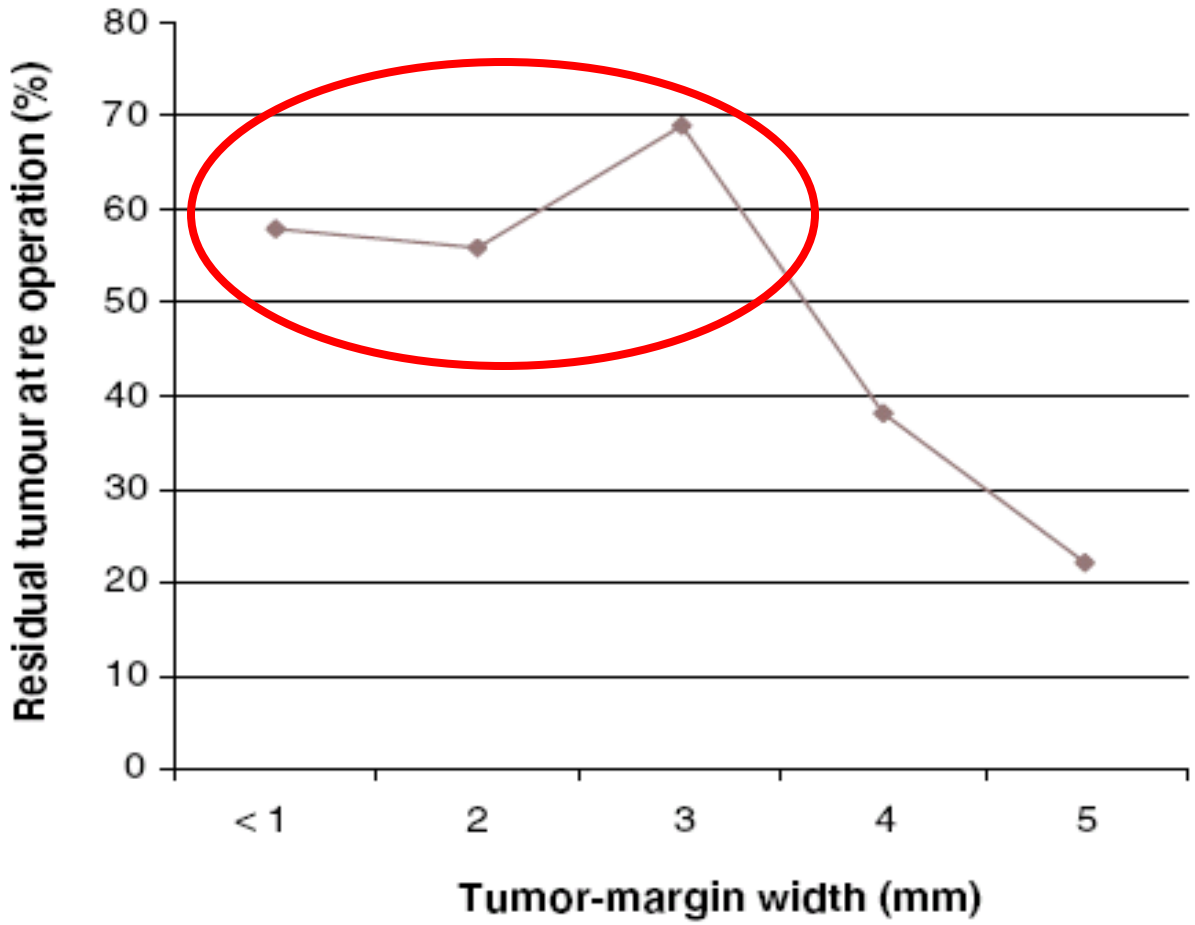

FIG. 1. Tumor-margin distance related to the presence of residual disease found at reoperation. $P = .03$; χ^2 test for trend.

Dillon et al Ann Surg Onc 2006

Residual Disease on Re-Excision by Initial Resection Margin Width

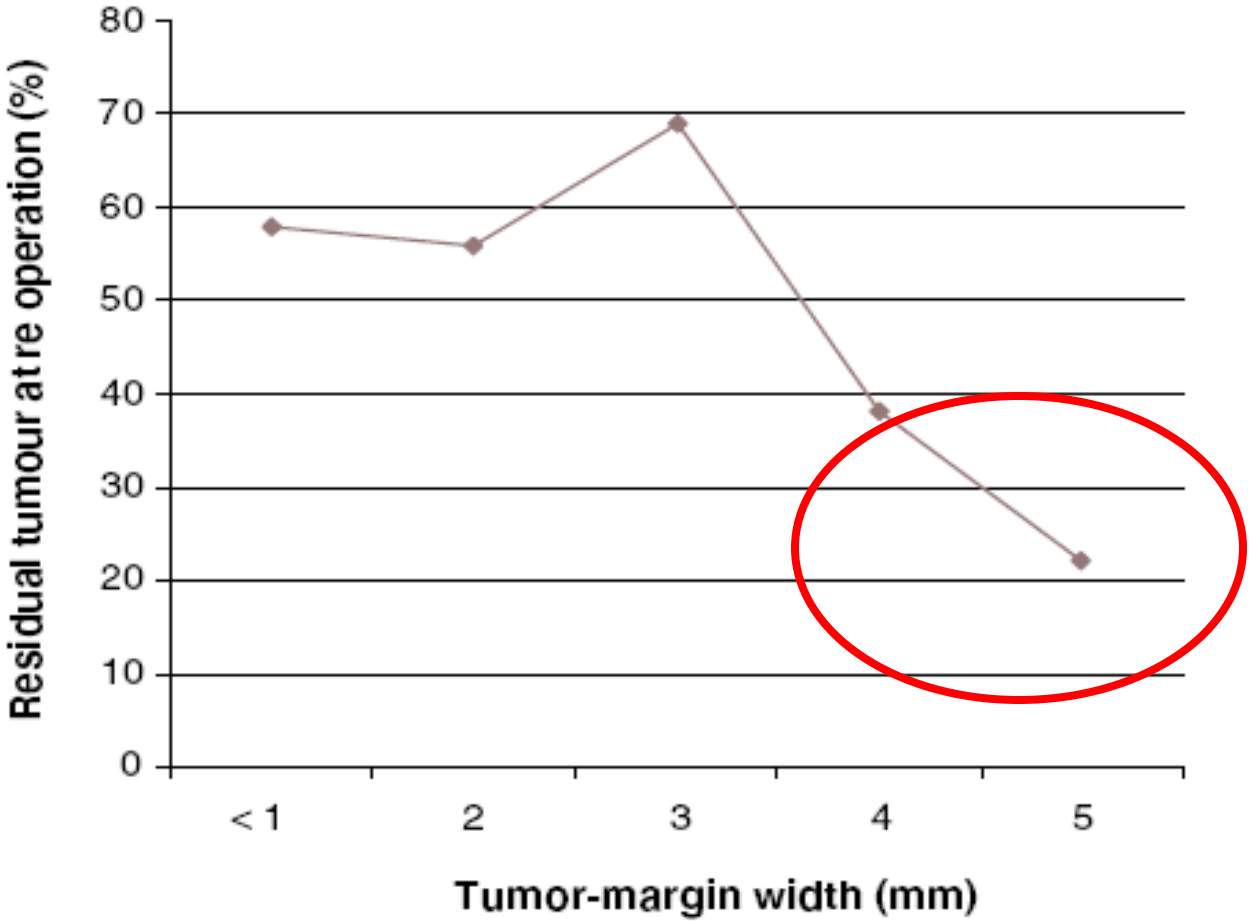

FIG. 1. Tumor-margin distance related to the presence of residual disease found at reoperation. $P = .03$; χ^2 test for trend.

Dillon et al Ann Surg Onc 2006

Breast Lumpectomy Margin Predicts Residual Tumor Burden in DCIS of the Breast

Residual Tumor Burden

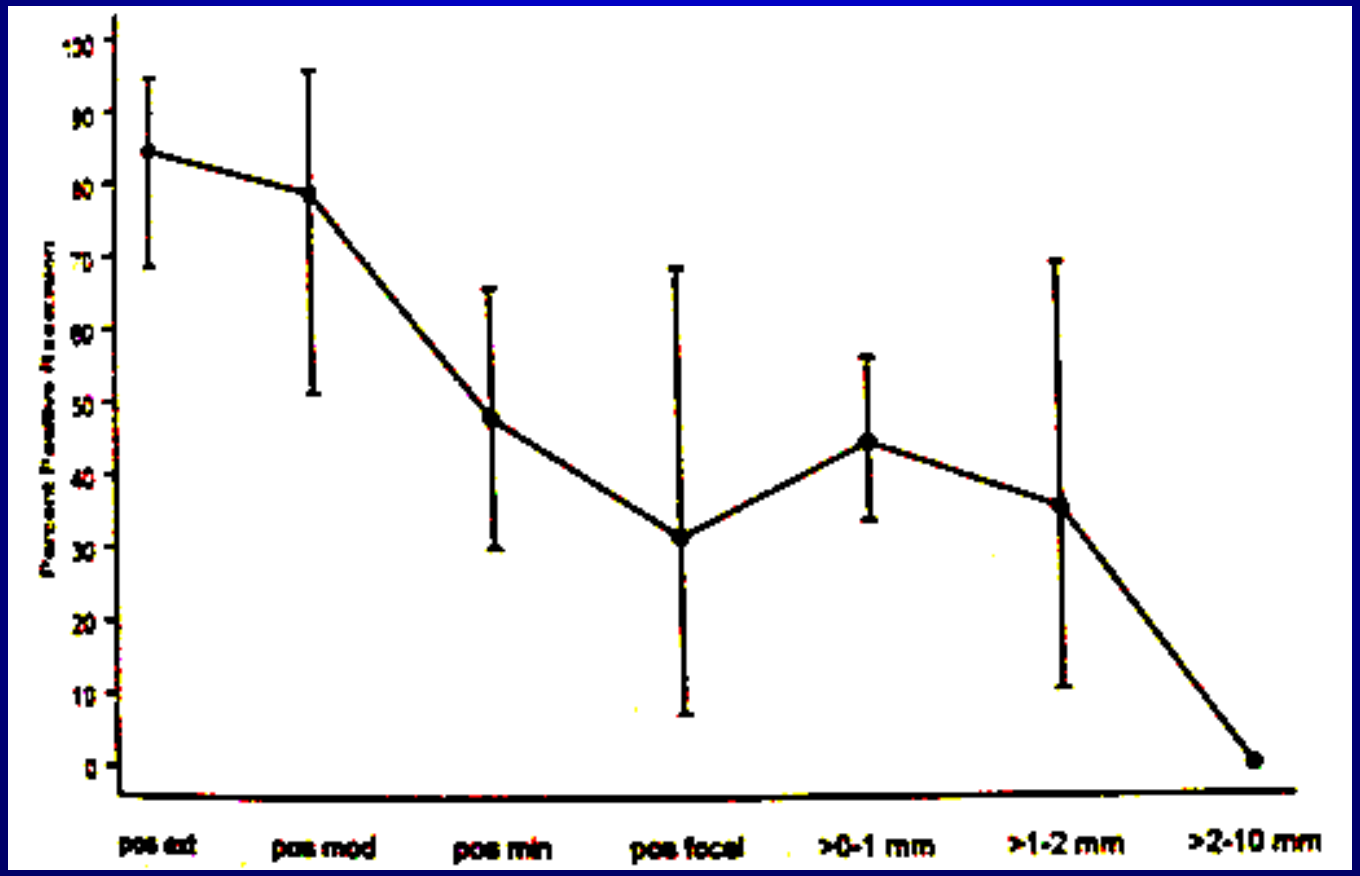

Initial Excision Margin

Neuschatz AC et al Cancer 94:1917-1924,2002

Disease Extension

- Holland R, et al. Cancer:56:979;1985
  - Gross Total Excision, T2
- Imamura H, et al BCRT 62:177;2000

  <64 y.o. - 8.32 mm

  ≥64 y.o. - 5.28 mm
- Ohtake T, et al.
  - Cancer 76:32;1995

  >50 y.o. - 6.7 – 7.7 mm
- Vicini T, et al. Reexcision - 90% <1 cm

eRFA Concept

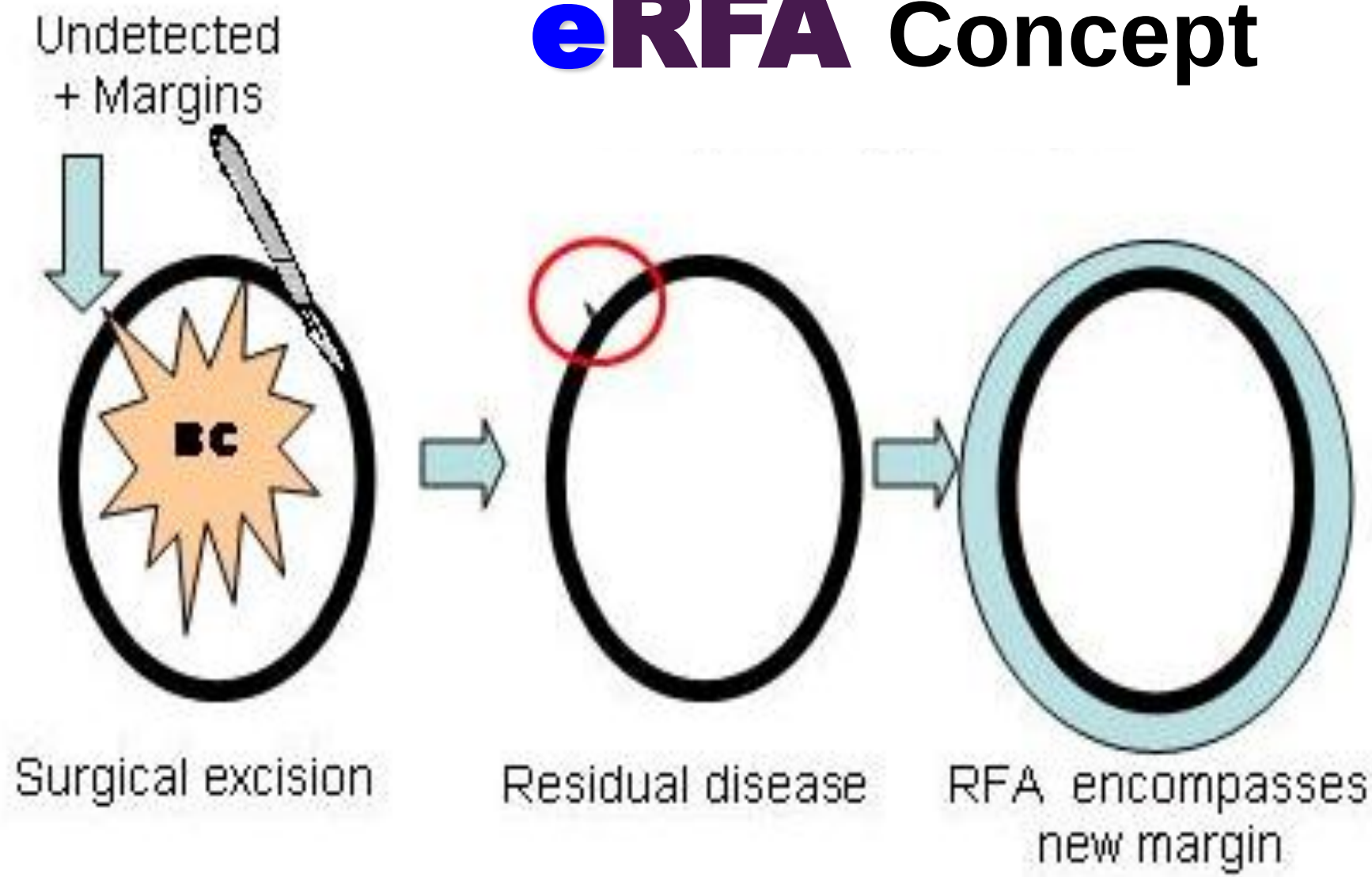

eRFA Simulated Lumpectomy

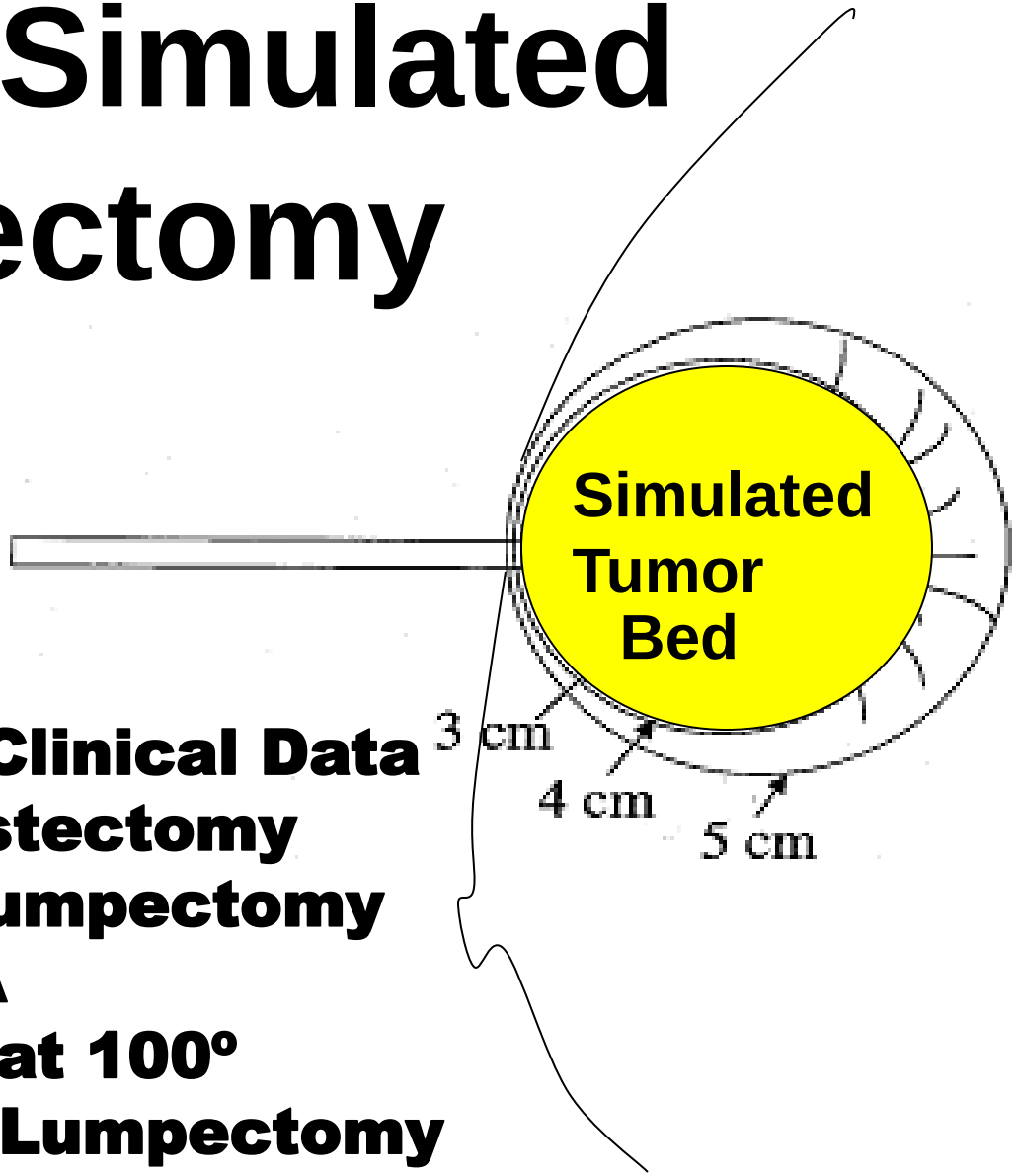

- **Obtain Pre-Clinical Data**
- ***Ex Vivo* Mastectomy**
- **Simulated lumpectomy**
- ***Ex Vivo* RFA**
- **15 minutes at 100º**
- **Excision of Lumpectomy**
- **Whole Mount Reconstruction**

Ex Vivo Simulated Lumpectomy



Ex Vivo Simulated Lumpectomy

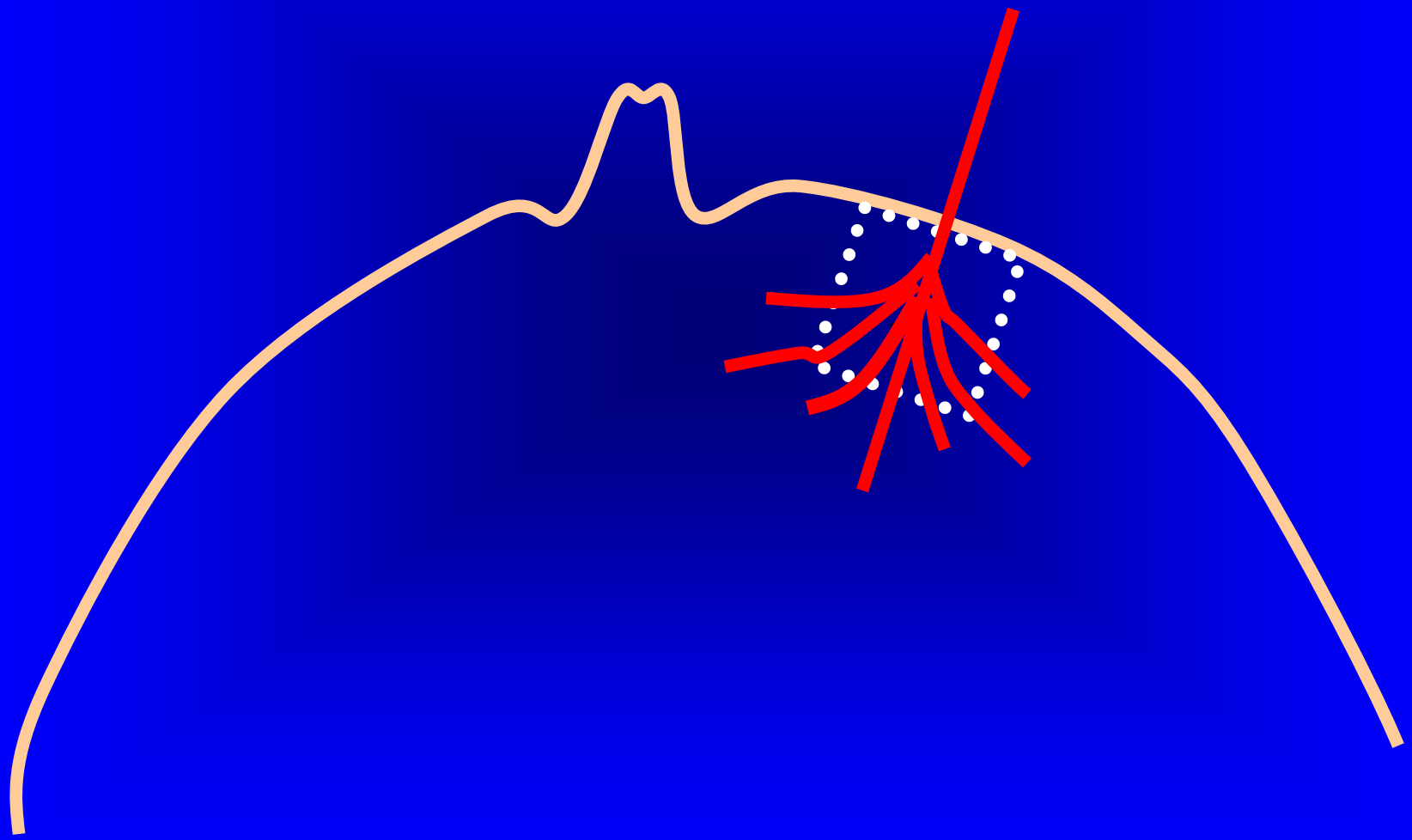

Ex Vivo Simulated Lumpectomy

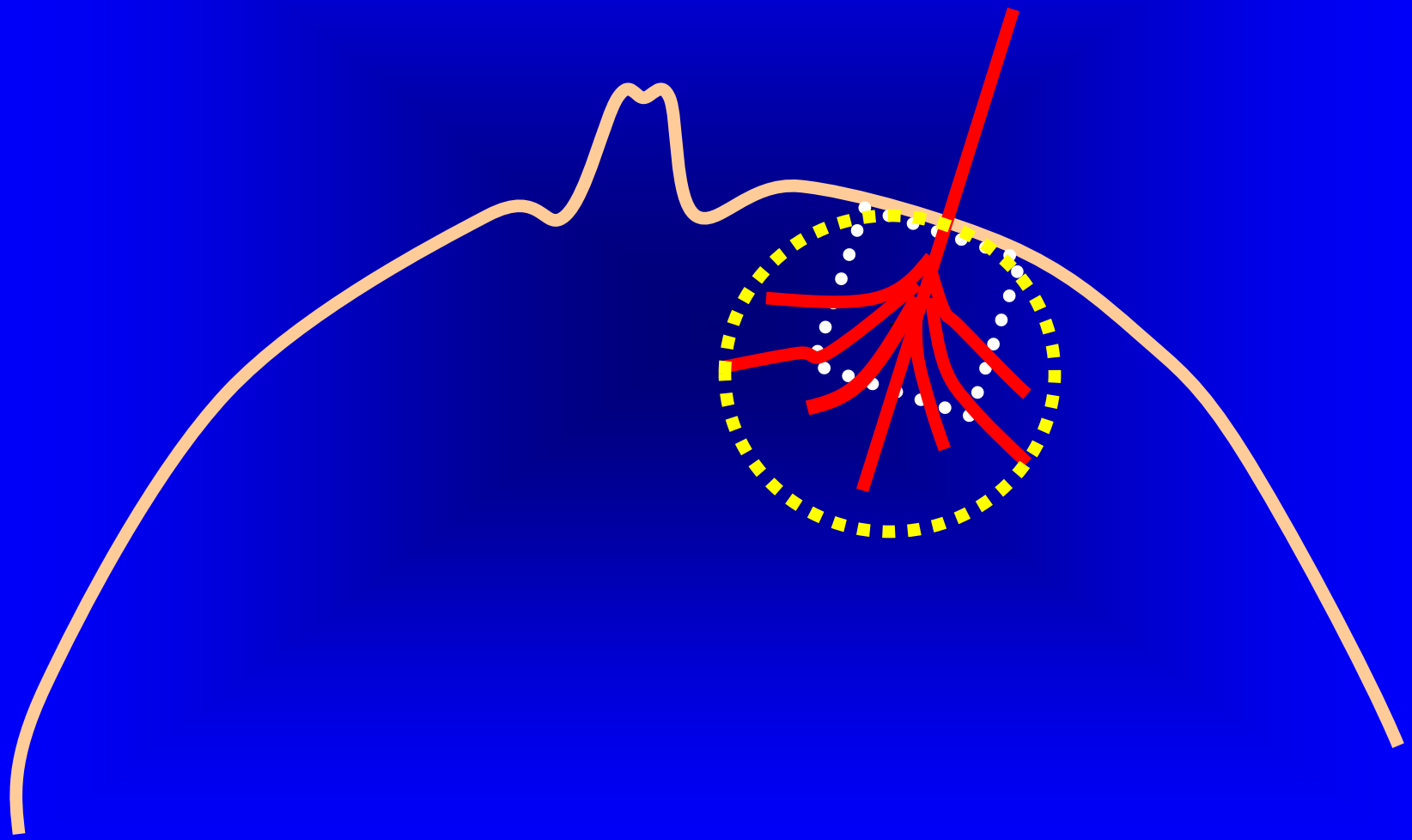

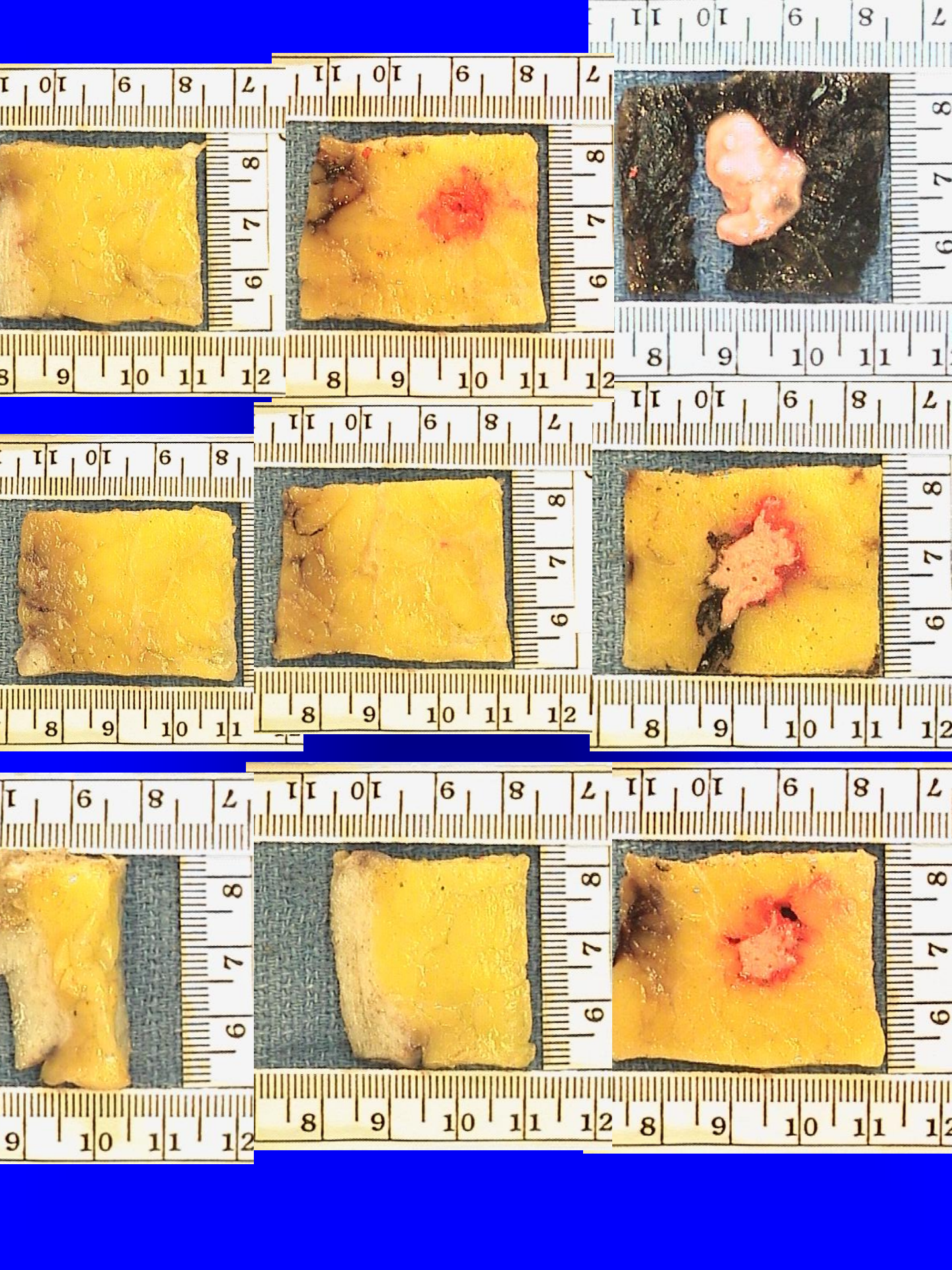

Lumpectomy Site Ablation

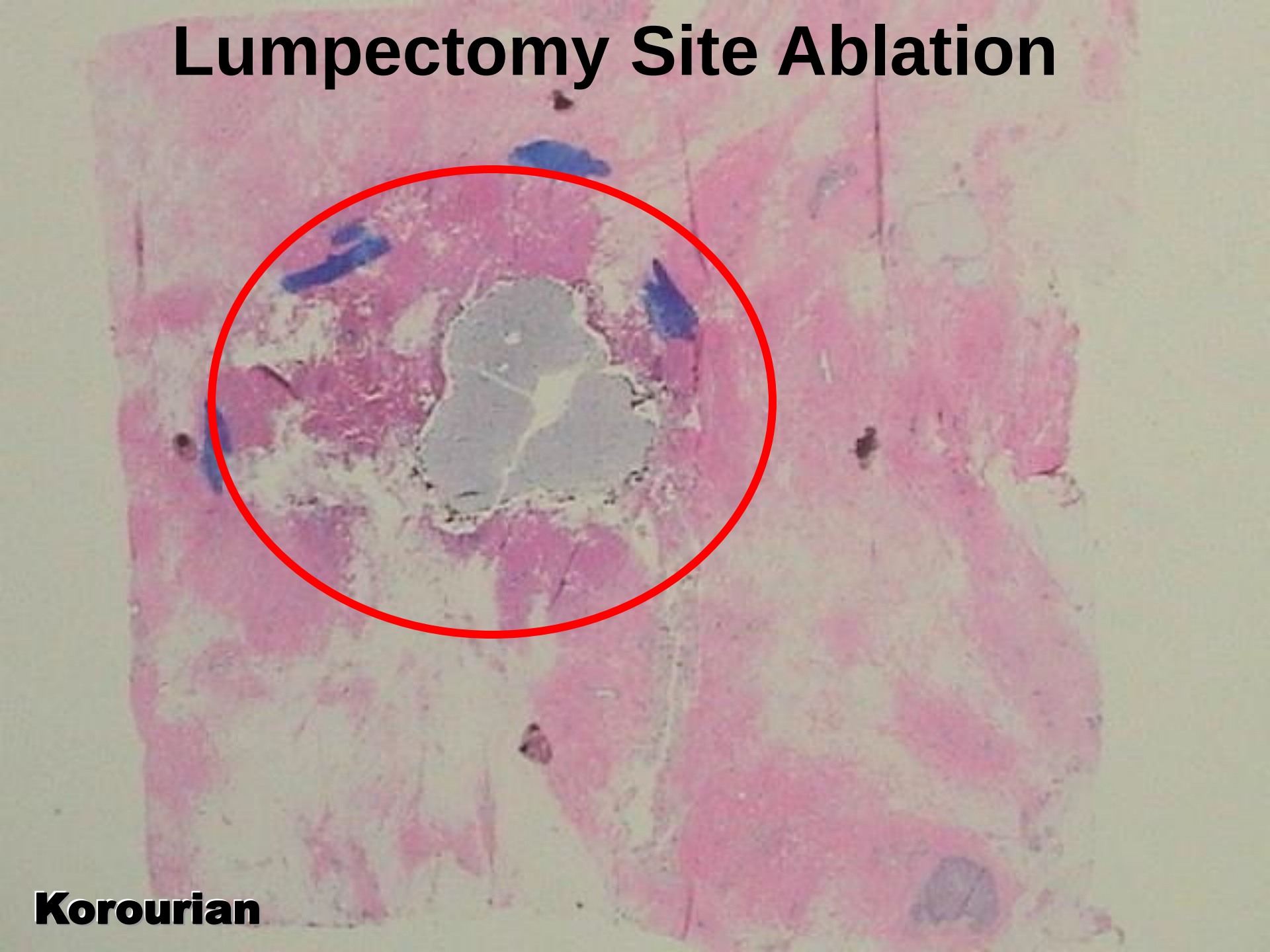

Korourian

Ex Vivo Simulated Lumpectomy

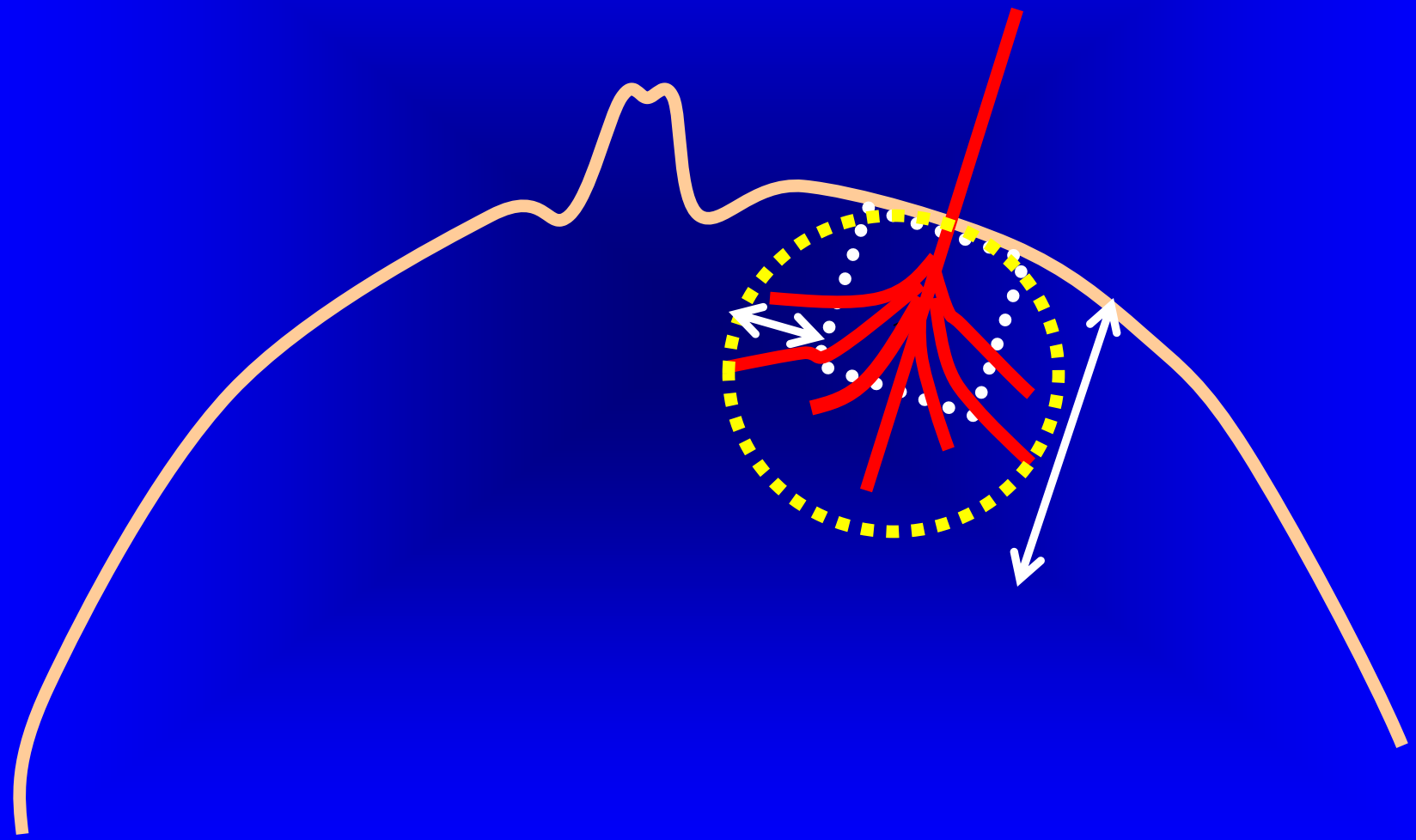

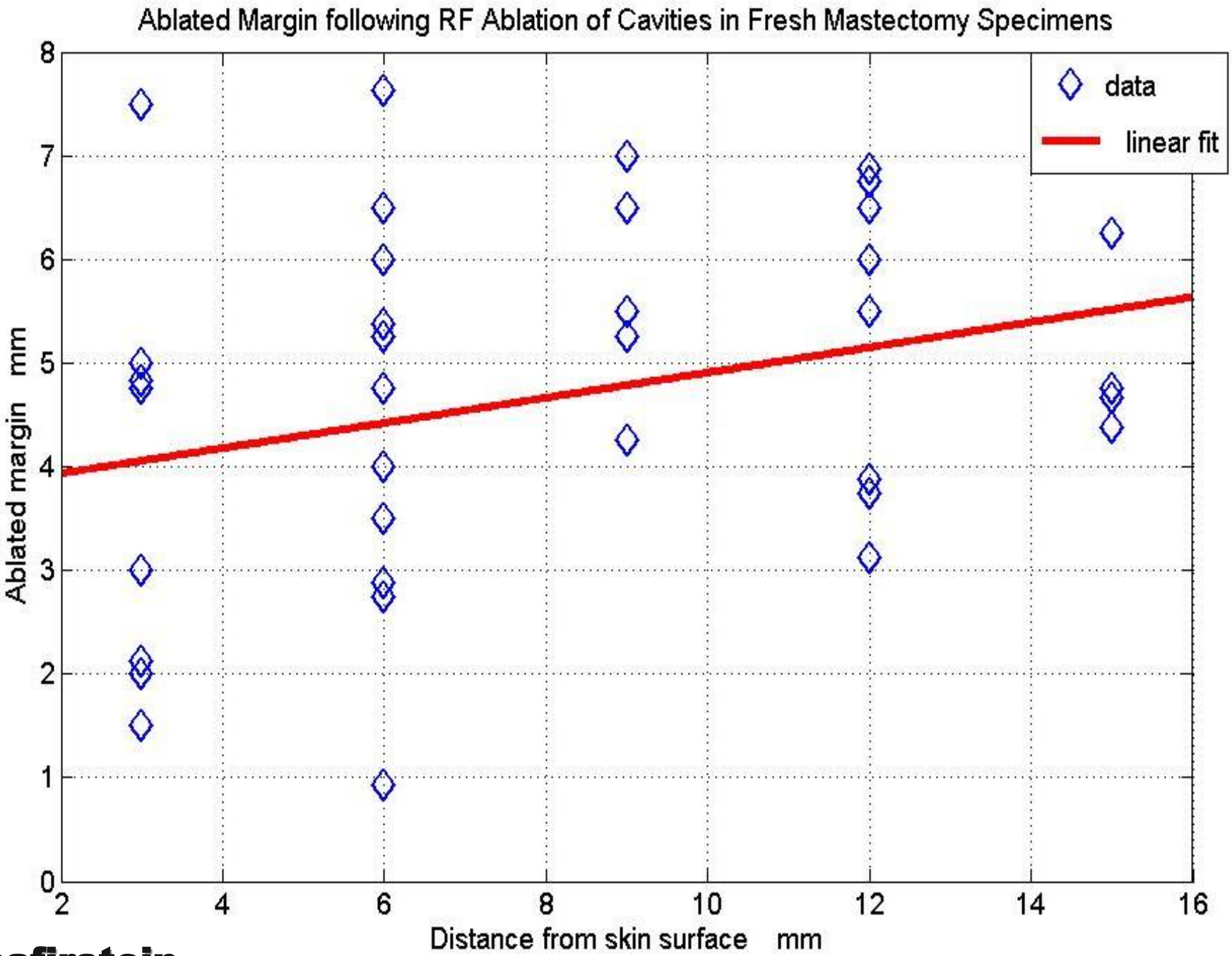

Shafirstein

3-D Reconstruction Of Lumpectomy Cavity Ablation

Gal Shafirstein, PhD

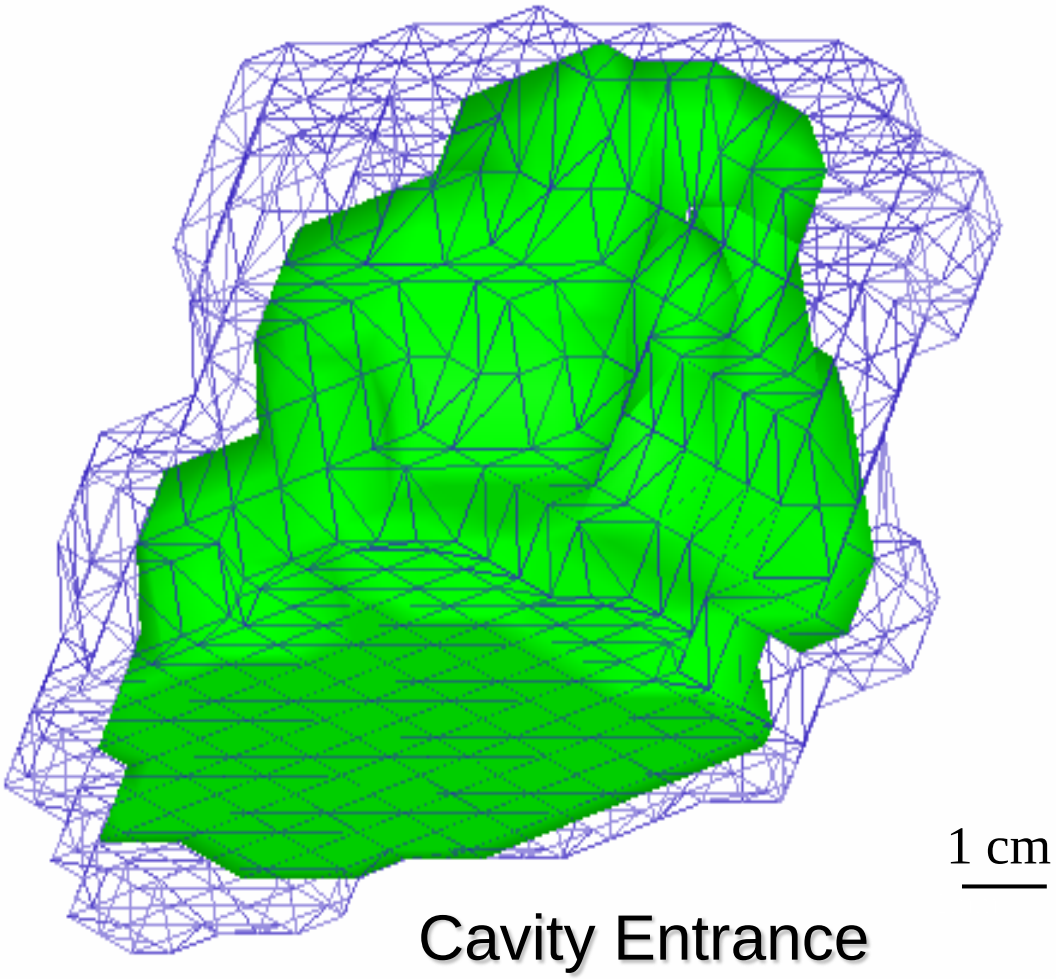



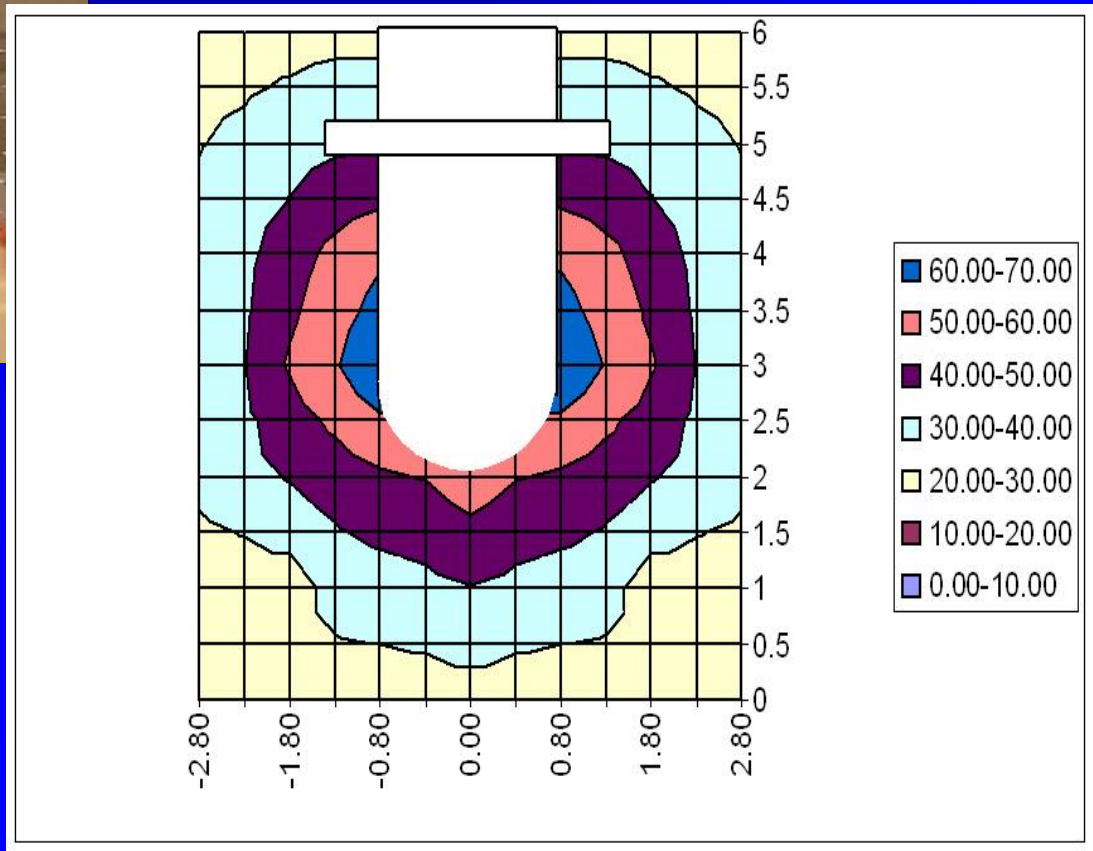
6
5.5
5
4.5
4
3.5
3
2.5
2
1.5
1
0.5
0
-2.80
-1.80
-0.80
0.00
0.80
1.80
2.80
60.00-70.00
50.00-60.00
40.00-50.00
30.00-40.00
20.00-30.00
10.00-20.00
0.00-10.00

Kwan

Simulated Lumpectomy & eRFA

Coad

Todorova & Thomas et al

Molecular Margin

HSP 27

Cytoplamic & Membrane Staining

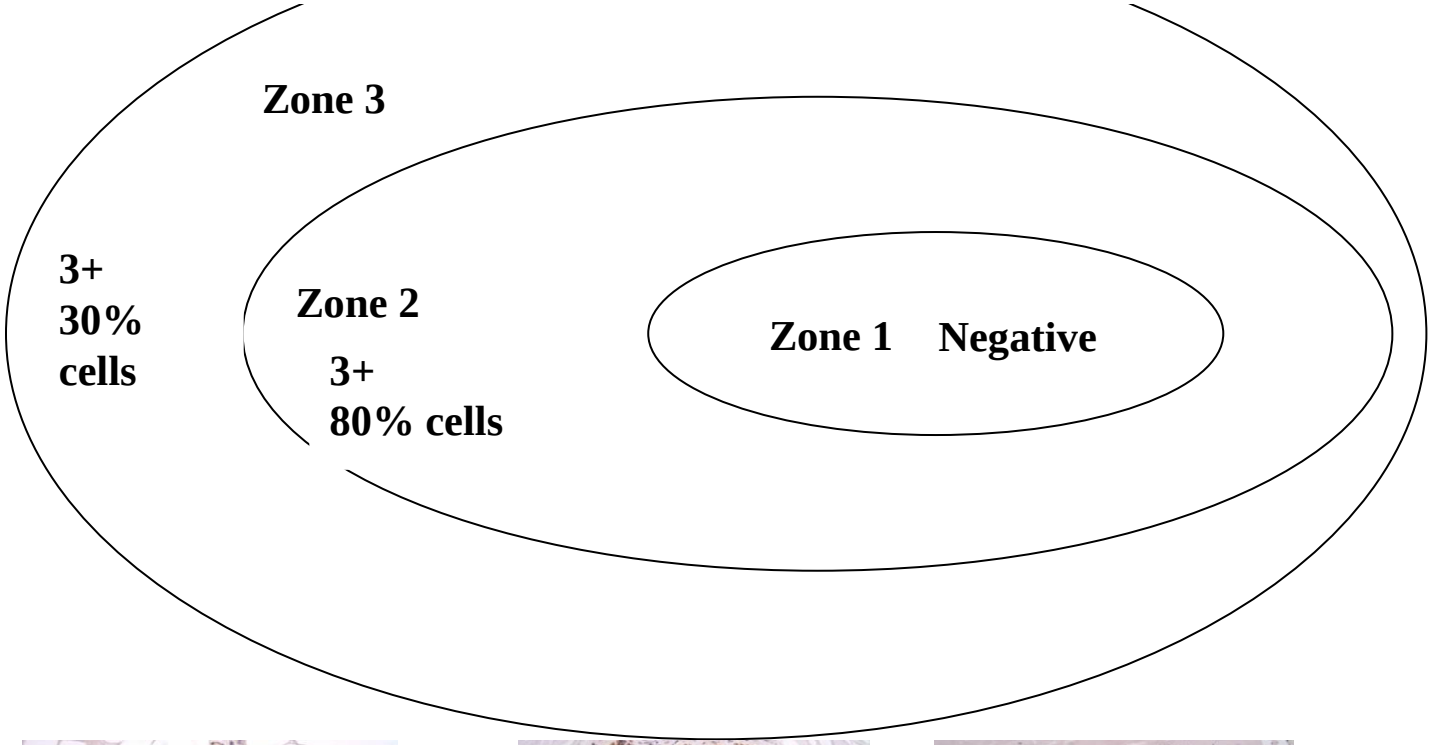

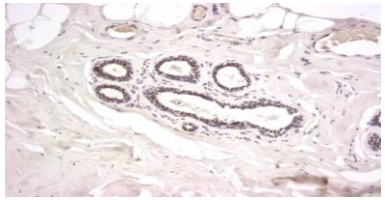

Zone 3

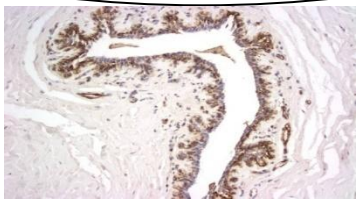

Zone 2

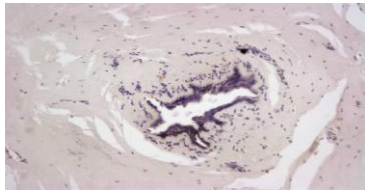

Zone 1 (ABLATION ZONE)

eRFA

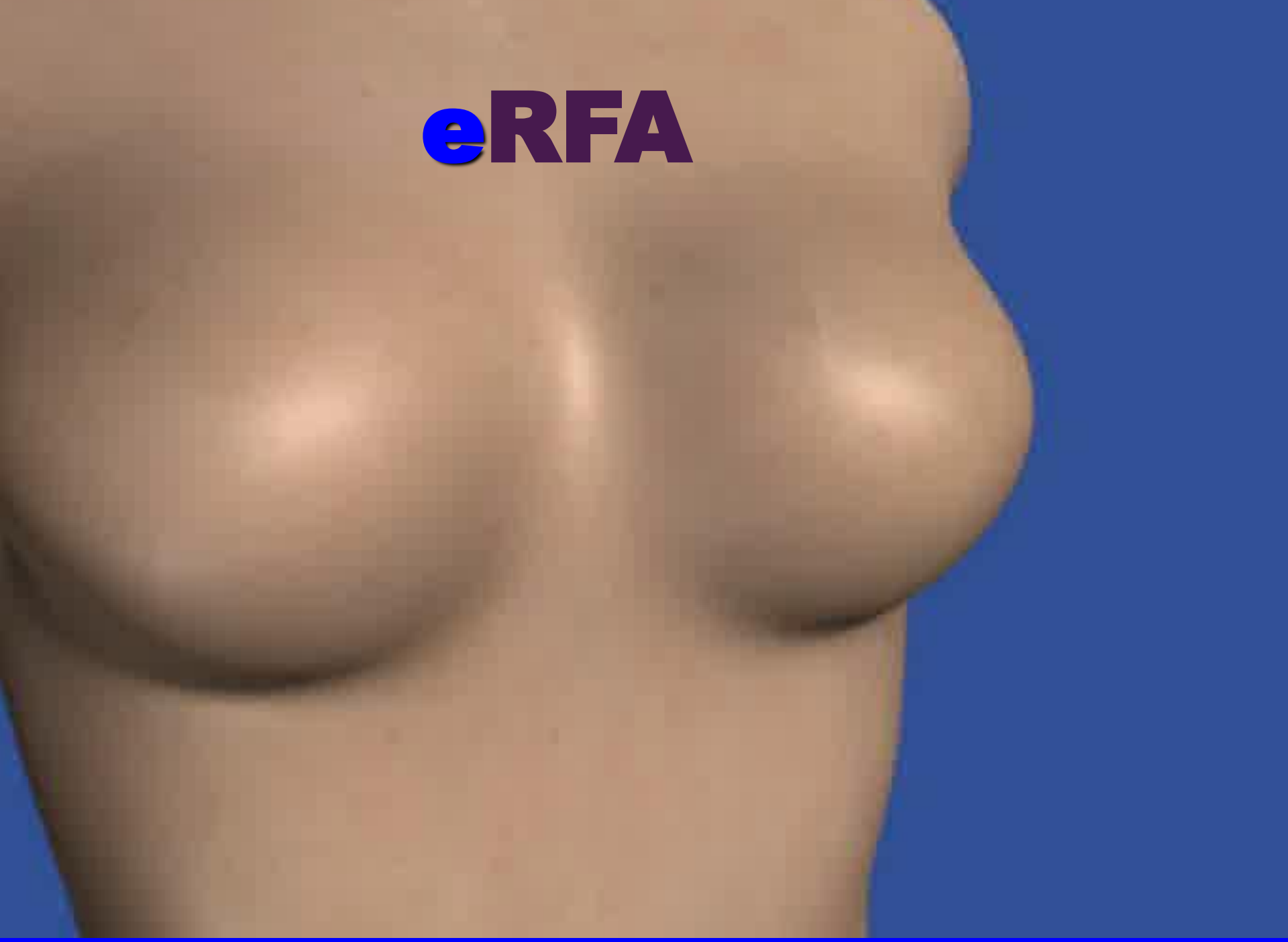

eRFA for Breast Cancer: Excision Followed by RFA

Real-Time Visualization of Cavitary Ablation



Cavitary Biopsies

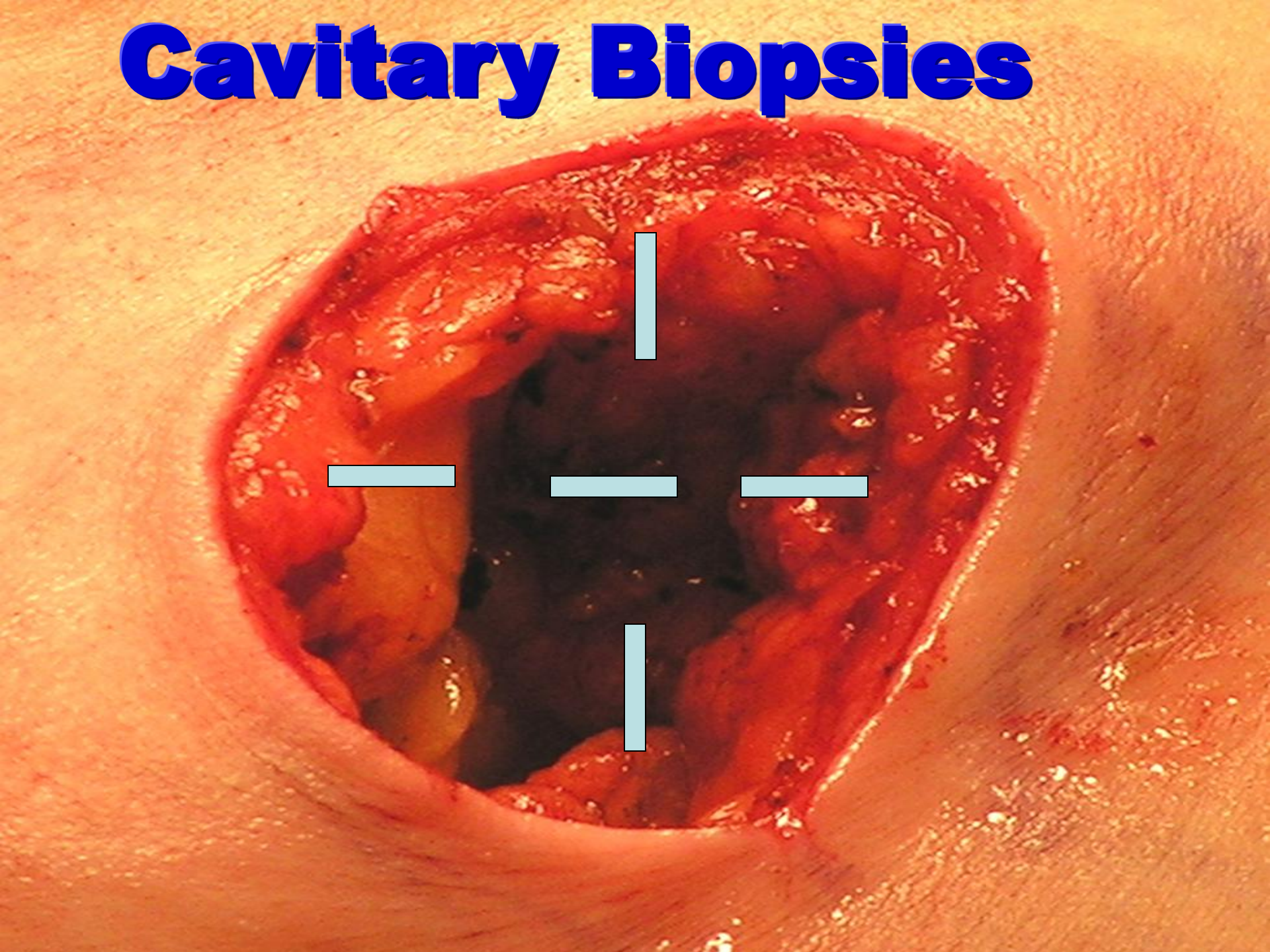

PCNA of Pre- & Post-Ablation RFA-Assisted Lumpectomy

- *Biopsies of Ablated Cavity all ≥ 12±5 mm*

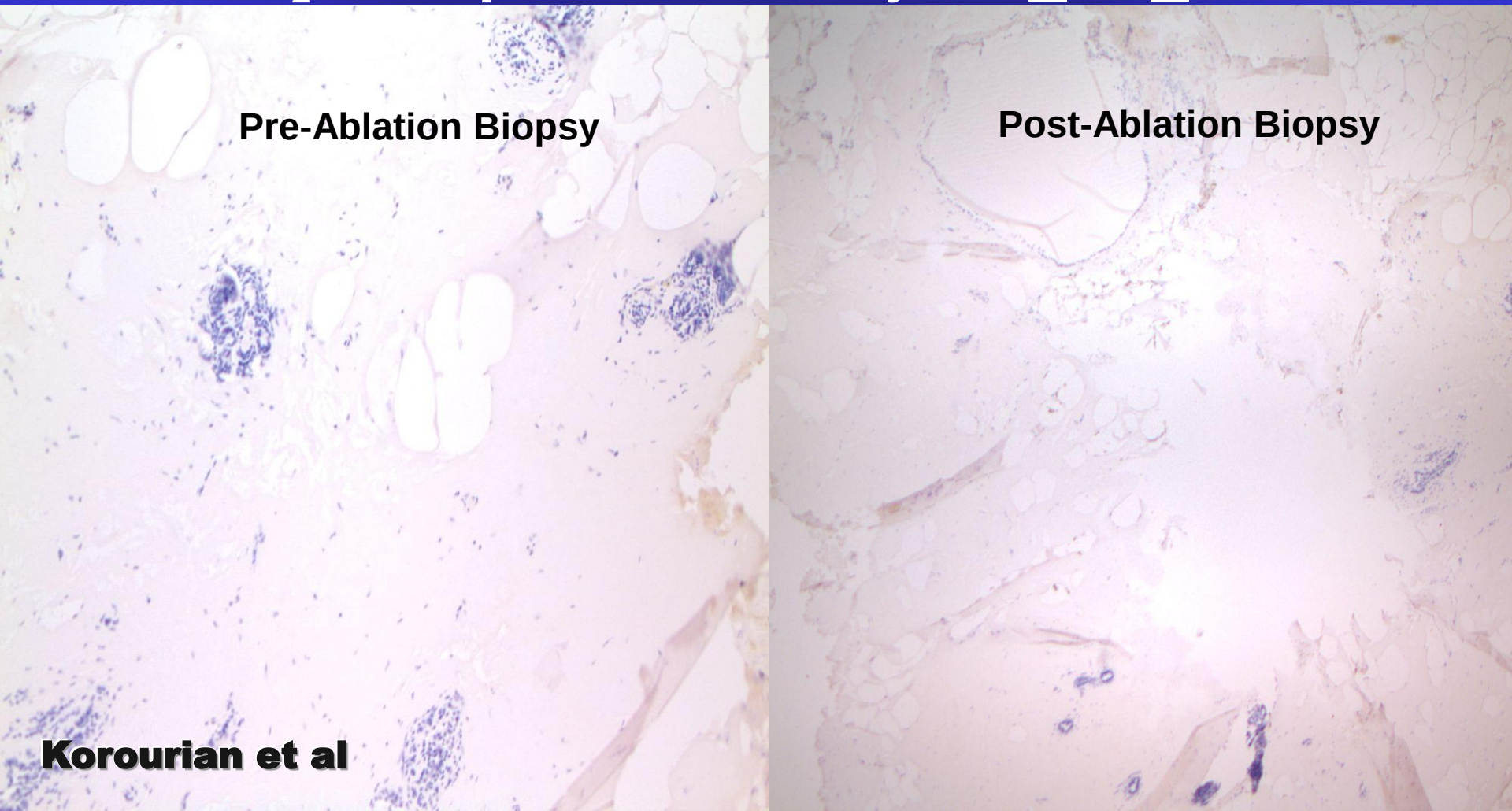

Korourian et al

PCNA of Pre- & Post-Ablation RFA-Assisted Lumpectomy

- *Biopsies of Ablated Cavity all ≥ 12±5 mm*

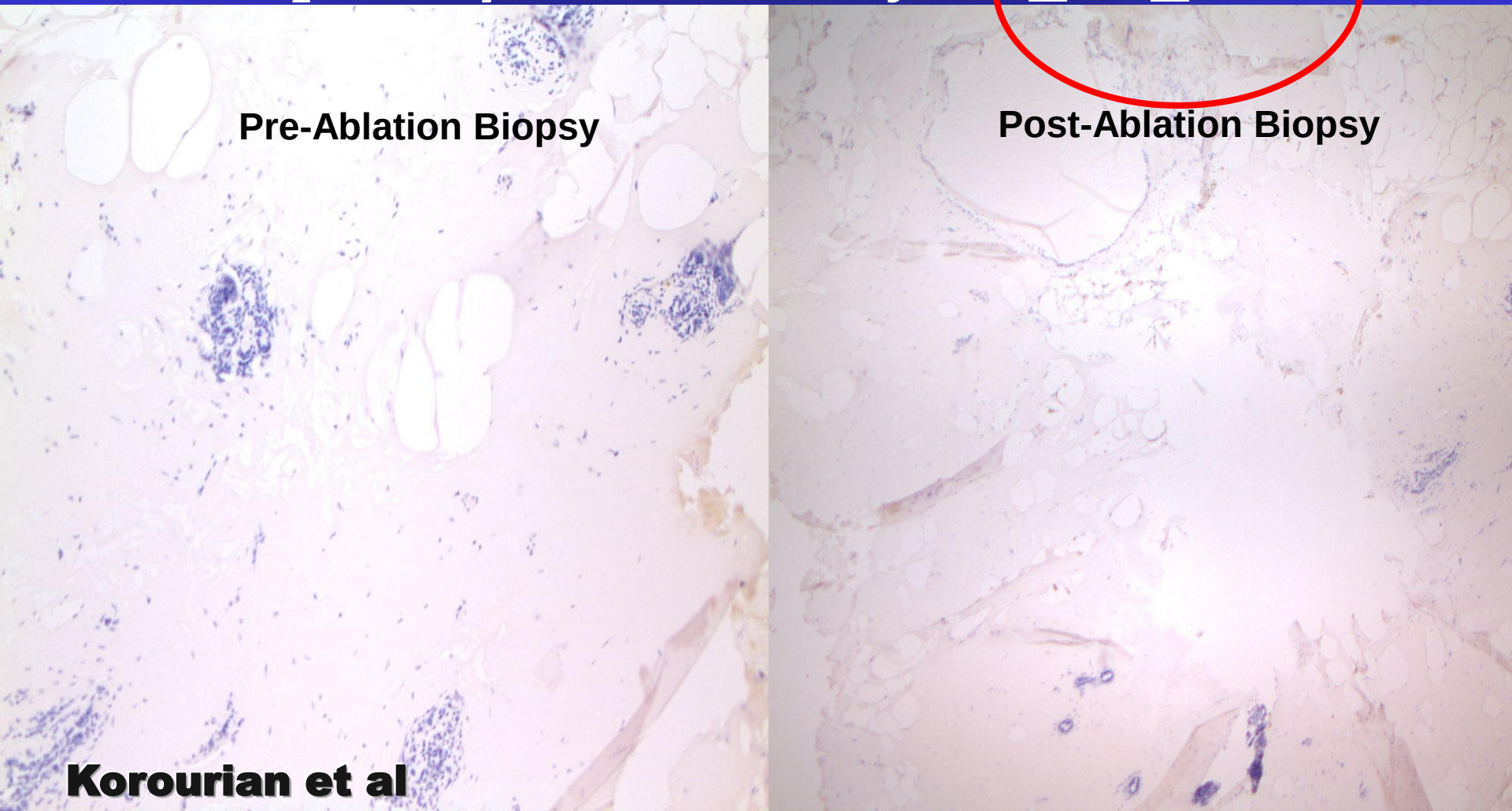

Korourian et al

6 months Post eRFA Without XRT

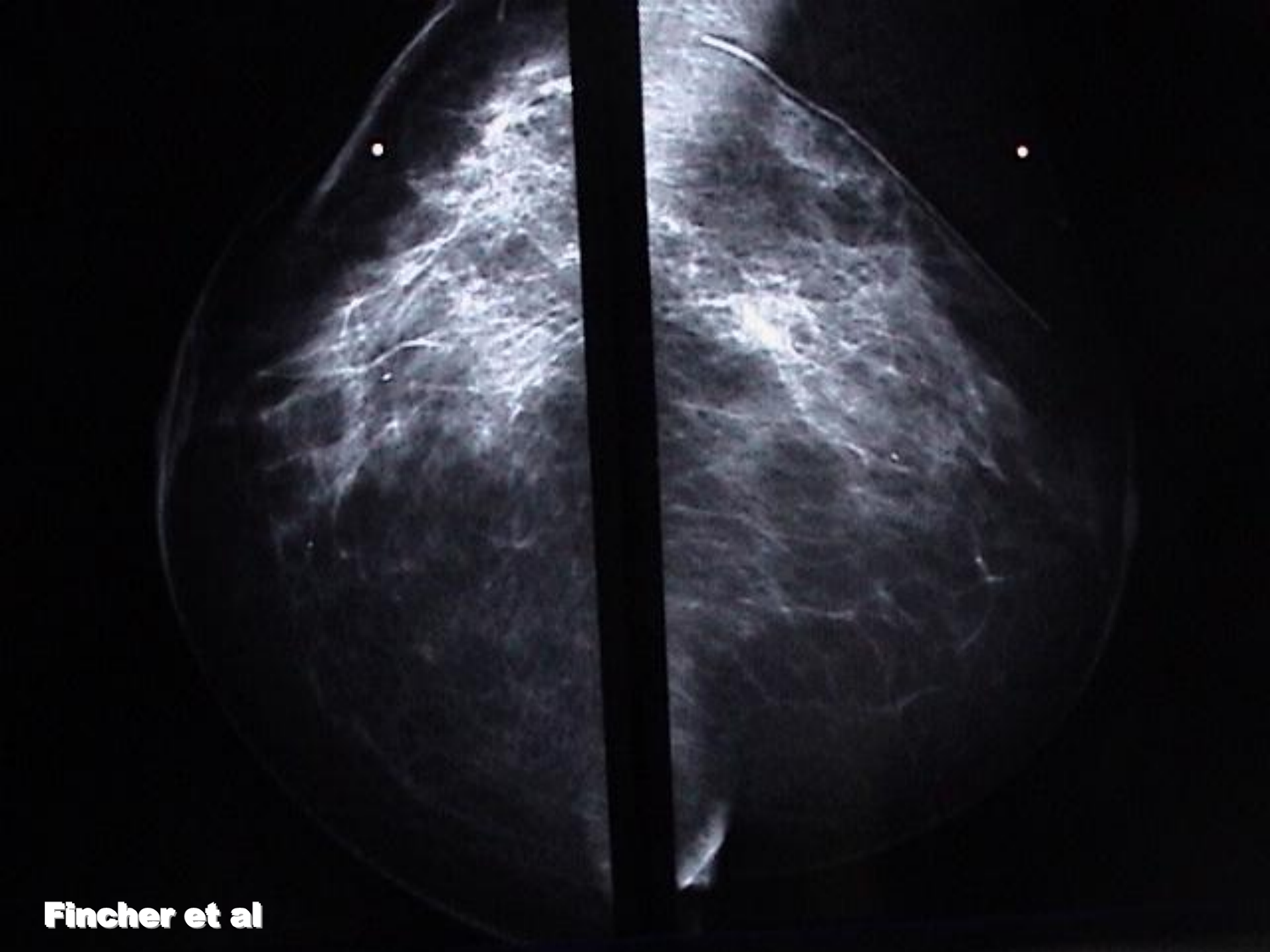

Fincher et al

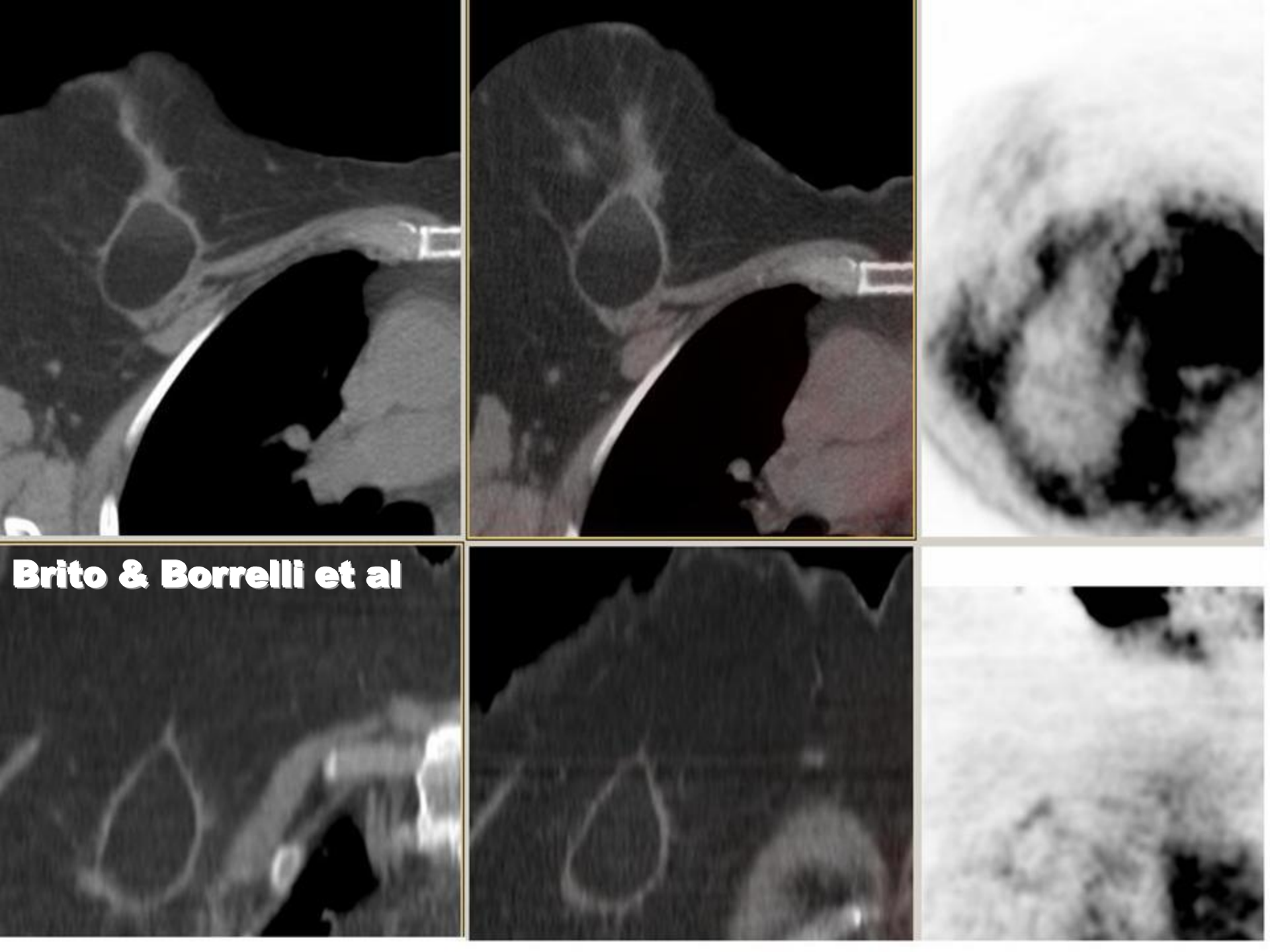
Brito & Borrelli et al

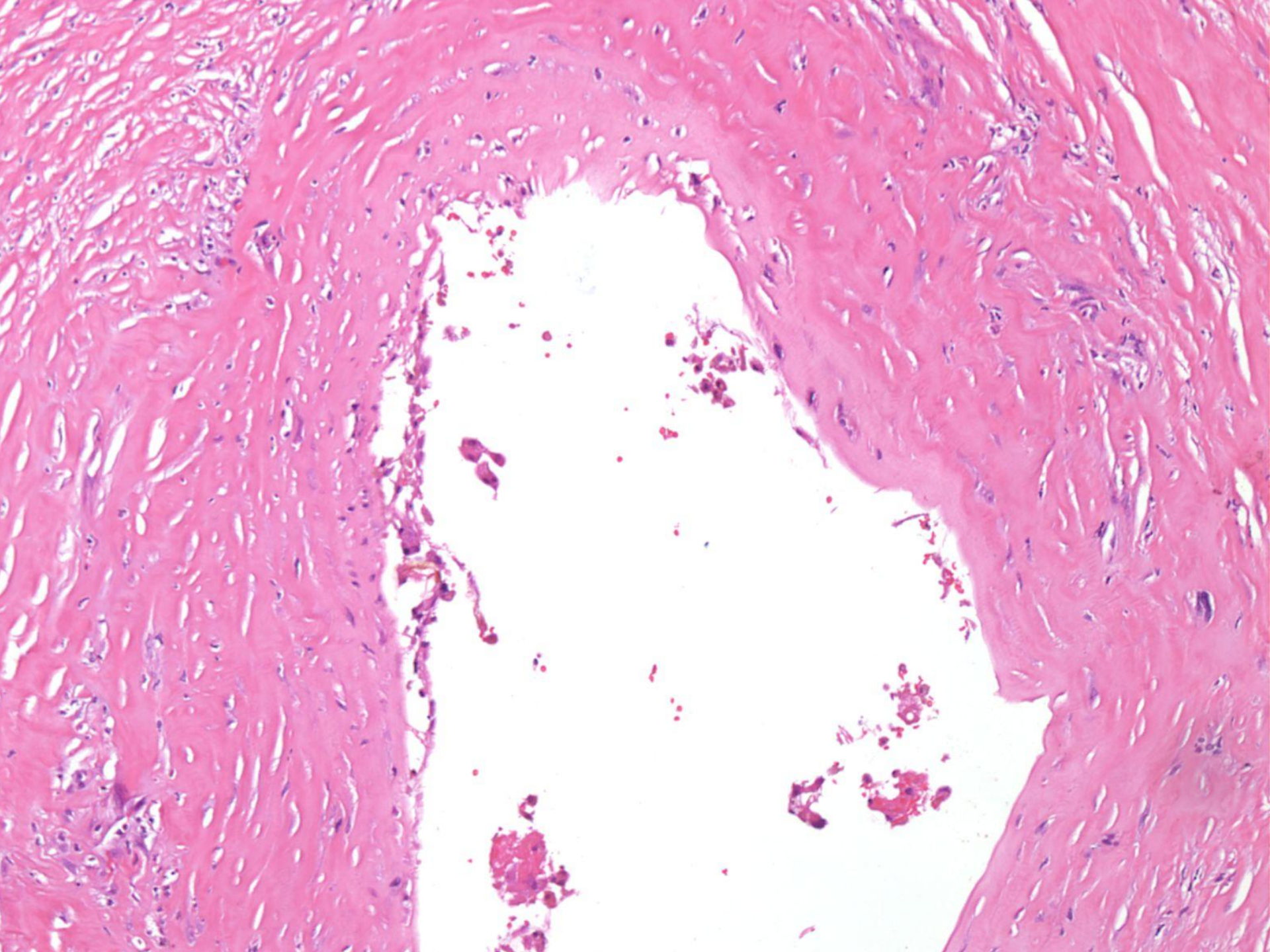

eRFA for Margins

Klimberg VS, Korourian S, Kepple JA, Henry-Tillman RS, Shafirstein G
Annals of Surgical Oncology

- 41 Pts with DCIS, T1 & T2 IBC for CBS
- Tumor Size: 1.5 ± 1.1 cm
- All patients had lumpectomy and RFA
- 24 Month Median Follow-up
- Results:
  - 25% had Inadequate Margins of ≤ 2 mm
  - ~1/2 of All Pts Benefited
  - *Very Good cosmesis and imaging results*

eRFA

Positive IOP Margins

Negative IOP Margins (41)

Re-Resection

Final Path

1 Grossly+

10 Close/+

31 Neg

8 ≤2mm

1 Focally +

9

~8 Occult +Margins**

F/U

Potential RFA Impact

9* + 8 = 17/40**

43% of All Pts

eRFA

Klimberg VS, Korourian S, Kepple JA, Henry-Tillman RS, Shafirstein G

- 80 Patients
- 24 Mo Median Follow-up (Range 7 to 55 Mo)
- Results:
  - 60 did not have XRT after eRFA
  - 4 Had XRT Prior to eRFA
  - 2 Re-Excised for Remaining Calcifications
  - 2 Re-Excised for Grossly Positive Margins
  - No Insite LR
  - 2 Elsewhere Recurrence
  - Post op Complications – 7.5%

Potential Advantages of eRFA in Breast Cancer

- ↓ Re-Excisions
- ↓ Recurrences
- For Treatment of Favorable Breast Cancers
- Salvage after LR in Irradiated Breast
- Replace Boost in T2 Cancers
- May Impact Survival

Training in eRFA For Breast Cancer

- Italy
- Spain
- Germany
- Canada
- United States >10 States
- Registry Starting
- klimbergsuzanne@uams.edu

Italian Trial

- Lumpectomy + eRFA
- Followed by Quadrantectomy
- Determine Margin Ablation

In Vivo Primary Lumpectomy Ablation

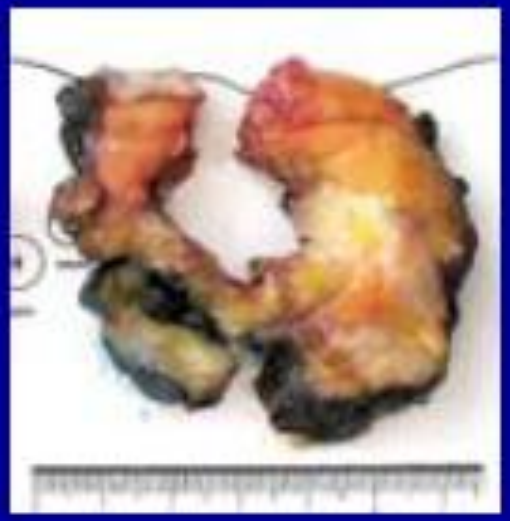

Coad

Italian Pathology Trial Cases

© Coad 2007

eRFA

Klimberg VS, Korourian S, Kepple JA, Henry-Tillman RS, Shafirstein G

- 80 Patients
- 24 Mo Median Follow-up (Range 7 to 55 Mo)
- Results:
  - 60 did not have XRT after eRFA
  - 4 Had XRT Prior to eRFA
  - 2 Re-Excised for Remaining Calcifications
  - 2 Re-Excised for Grossly Positive Margins
  - No Insite LR
  - 2 Elsewhere Recurrence
  - Post op Complications – 7.5%

Presently High Failure Rate after Lumpectomy Alone for Treatment of LR in the Radiated Breast Mandates Mastectomy

- 32% LRR for Excision Alone
- 51 Month Follow-Up

Kurtz et al

SWOG Concept: Excision Followed by RFA for Salvage of Recurrence Following Breast Conservation

Salvage eRFA

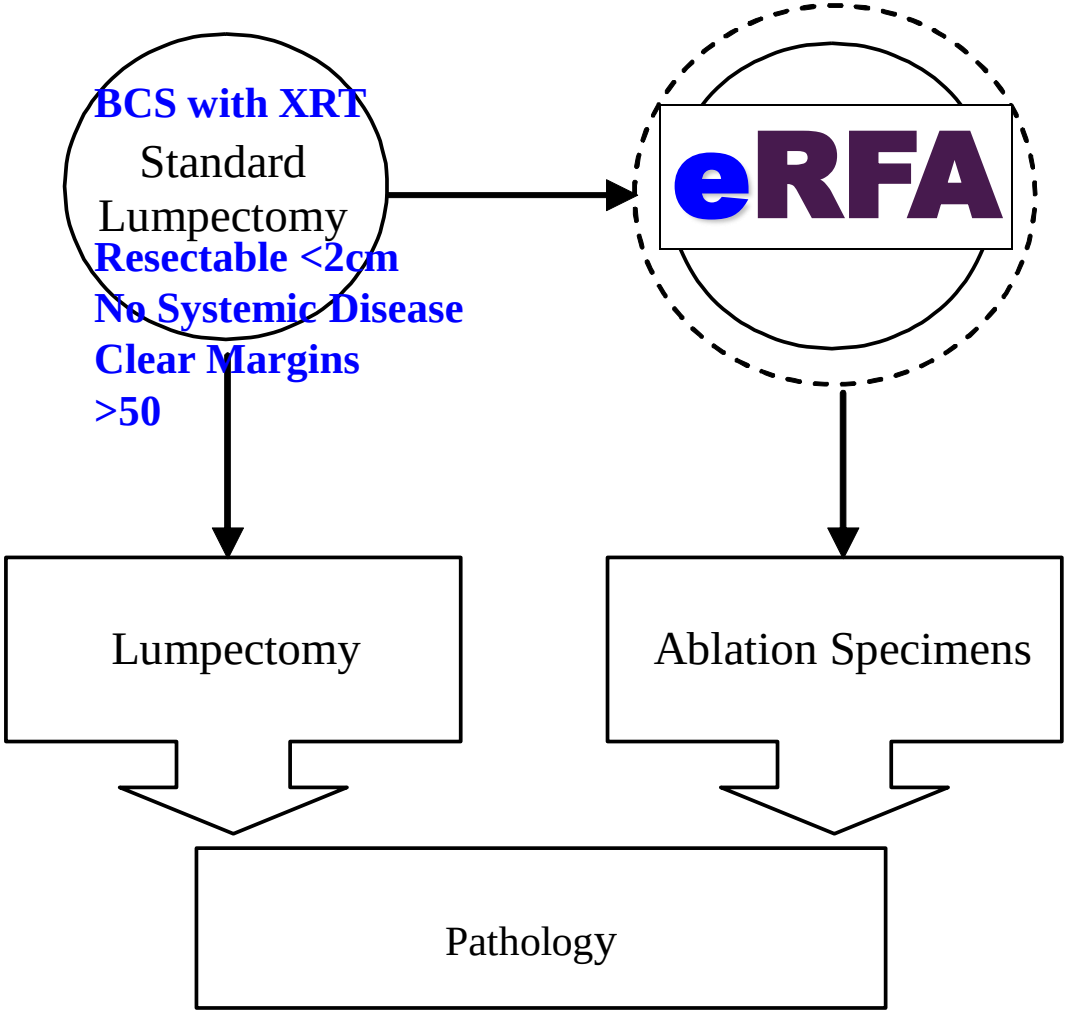

Adjuntive Breast Lumpectomy with RF Ablation Treatment to reduce re-Excision & recurrence: ABLATE Trial

DCIS or IDC < 2 cm

- **eRFA**
- **BCS with XRT**

Adjuntive Breast Lumpectomy with RF Ablation Treatment to reduce re-Excision & recurrence

ABLATE Registry

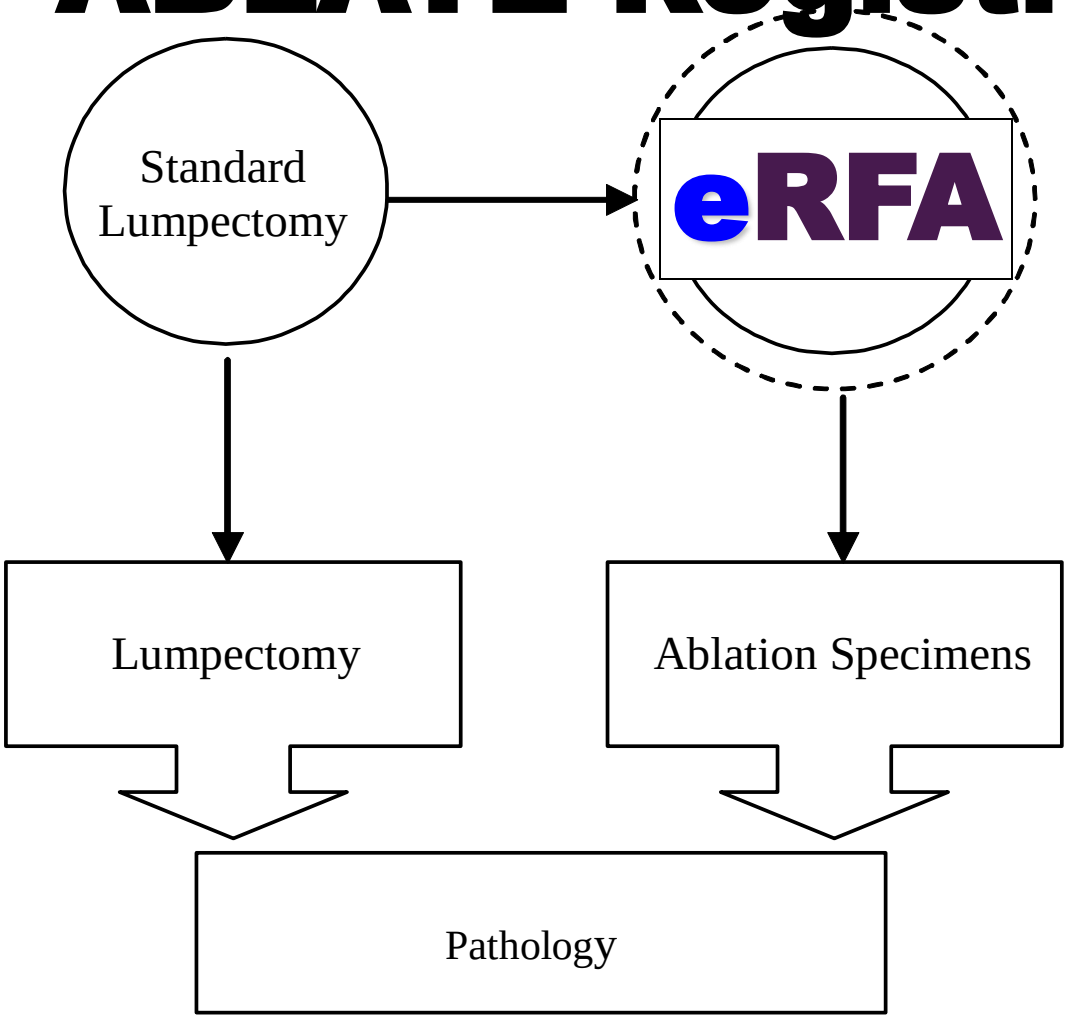

eRFA

May Represent a Paradigm Shift in the Treatment of Breast Cancer

The *Era*
is in the Margin

Axillary Reverse Mapping (ARM): A New Concept to Identify & Enhance Lymphatic Preservation

Staging of the Axillary Lymph Nodes

- **Staging of the Axillary Lymph Nodes is the Number 1 Predictor of How Well a Patient Will Do**
  - **CTX and XRT plans may change dependent upon the number and extent of axillary lymph node involvement.**
- **Techniques for staging the axilla have evolved from a level I-III or full axillary lymph node dissection (ALND) ~15-50% arm lymphedema rate.**

- **to a level I and II ALND**
  ~5-15% lymphedema rate.

SLN Concept

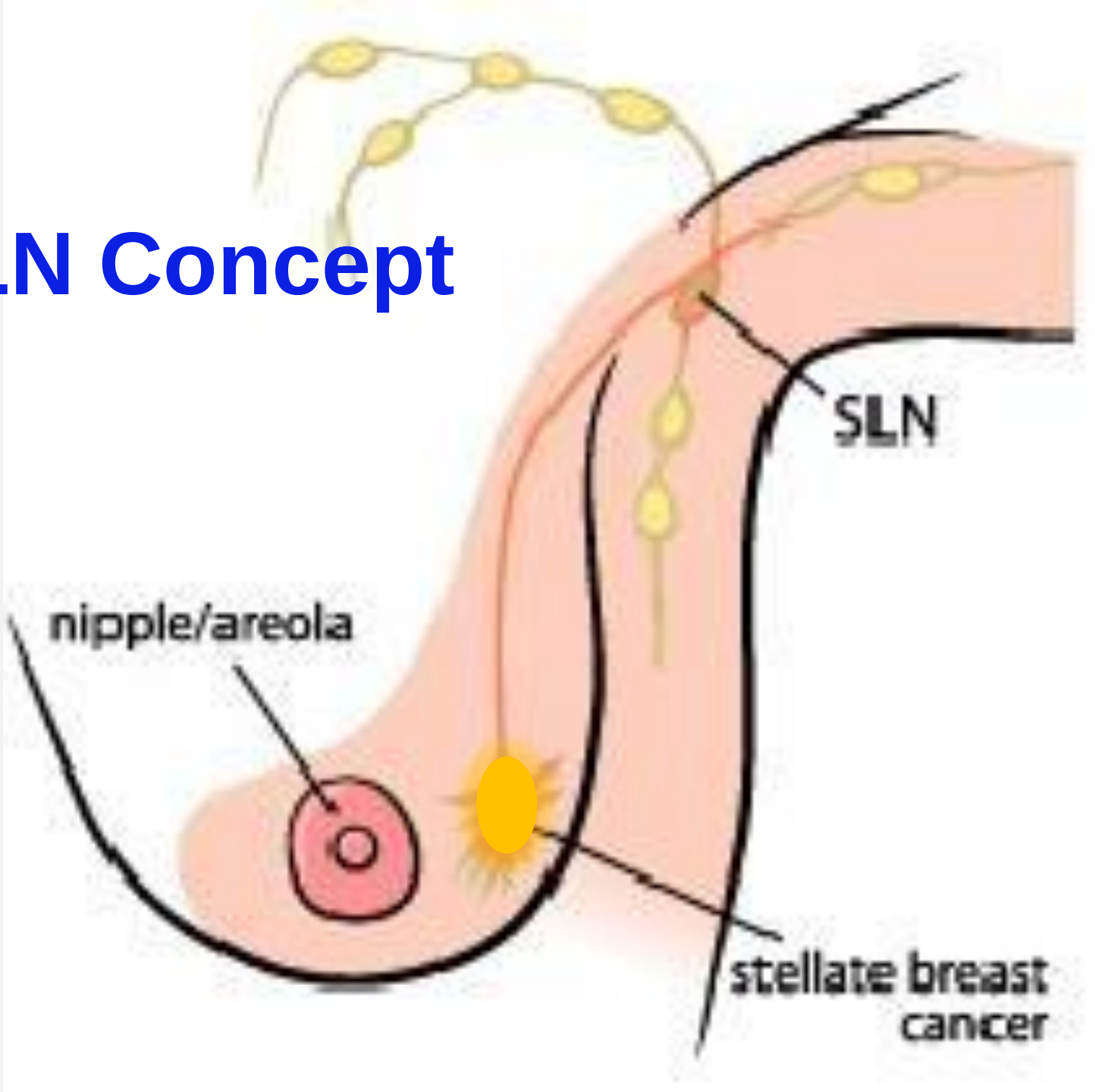

SLN Concept

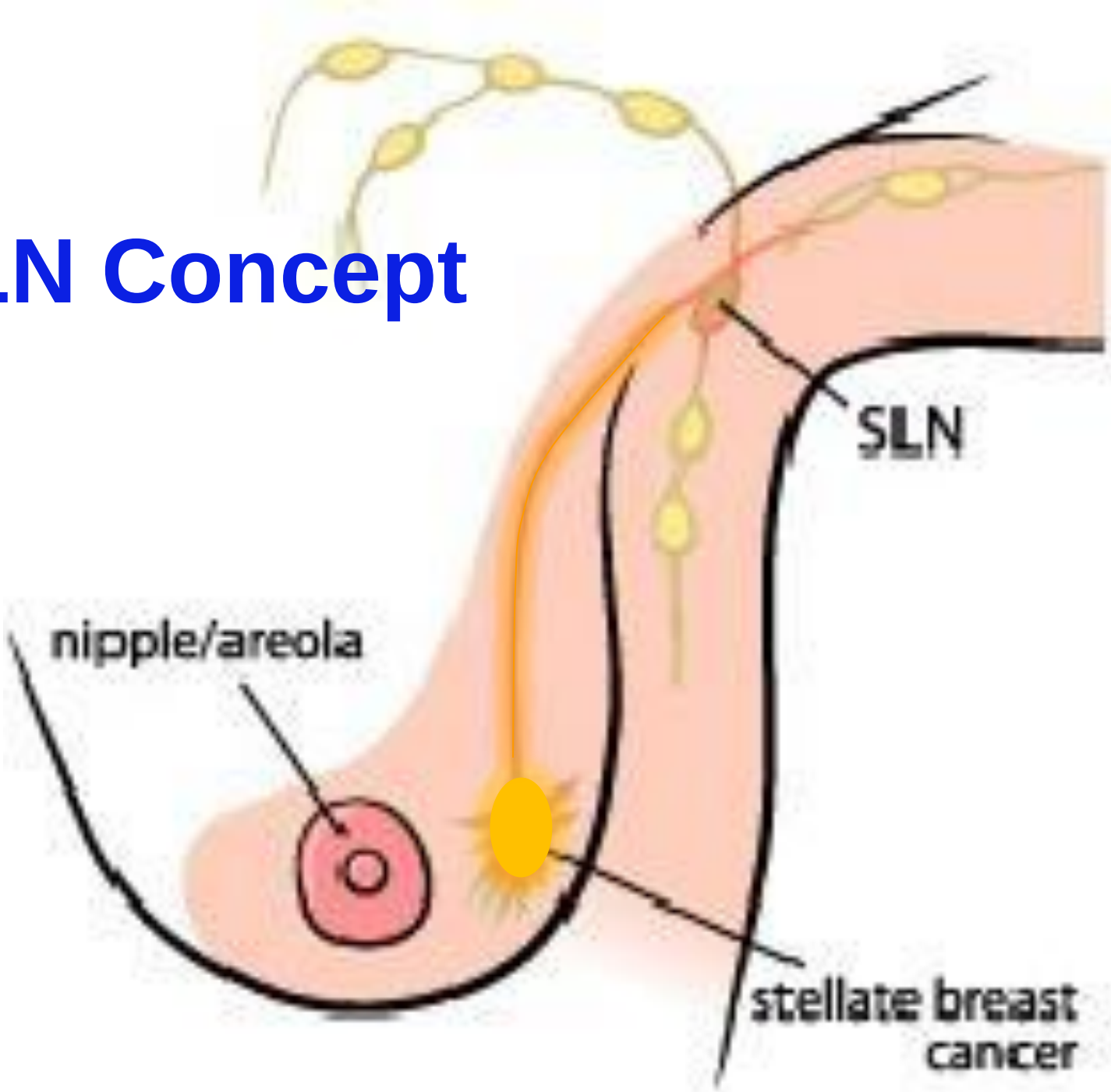

SLN Concept

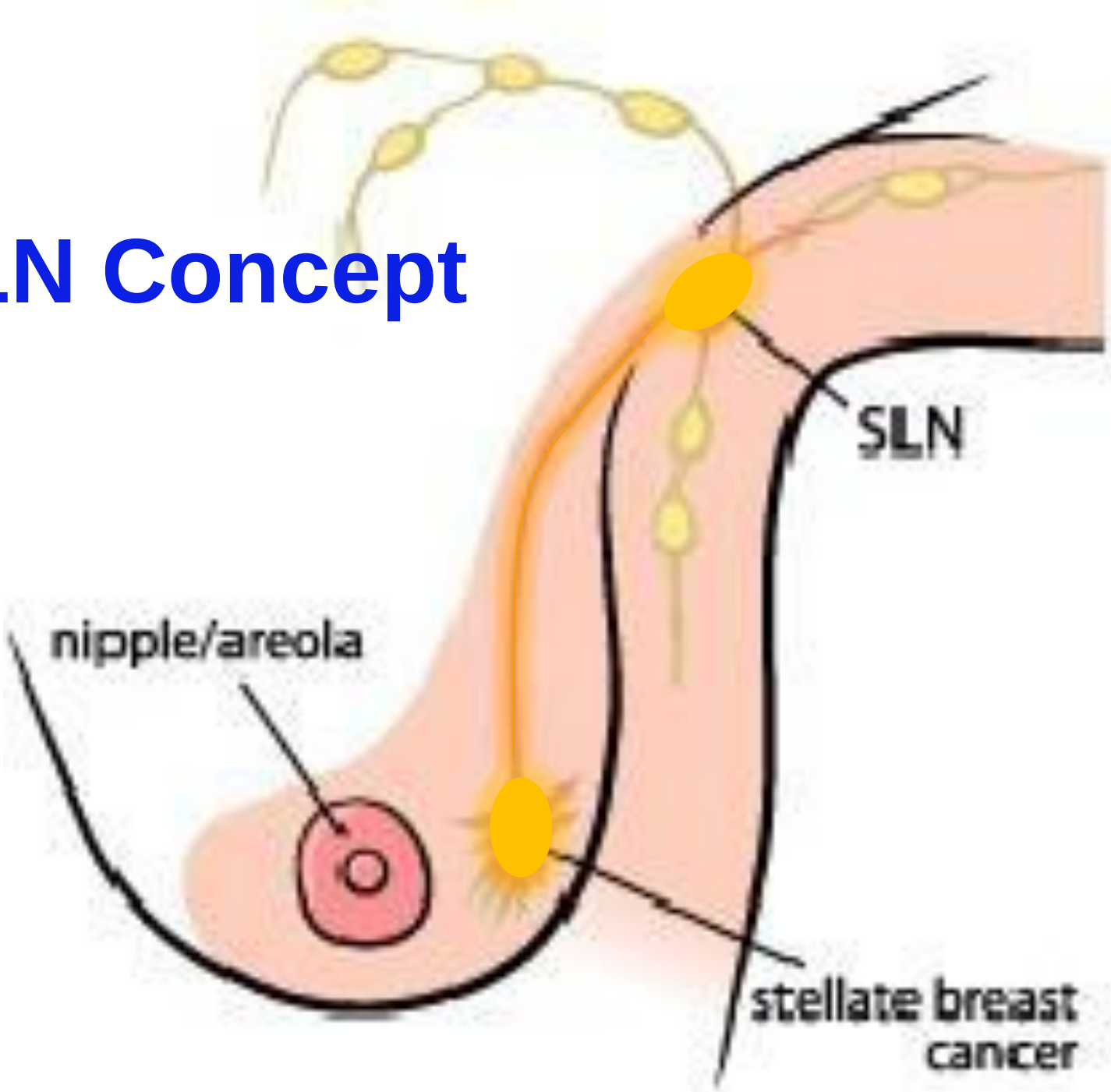

Staging of the Axillary Lymph Nodes

- **Staging of the Axillary Lymph Nodes is the Number 1 Predictor of How Well a Patient Will Do**
  - CTX and XRT plans may change dependent upon the number and extent of axillary lymph node involvement.
- Techniques for staging the axilla have evolved from a level I-III or full axillary lymph node dissection (ALND) ~15-50% arm lymphedema rate.

- to a level I and II ALND ~5-15% lymphedema rate.

- to that of SLNB ~1%-13%.

Hypothesis

We hypothesized that variations in arm lymphatic drainage put the arm at risk for lymphedema secondary to disruption during a SLNB &/or ALND.

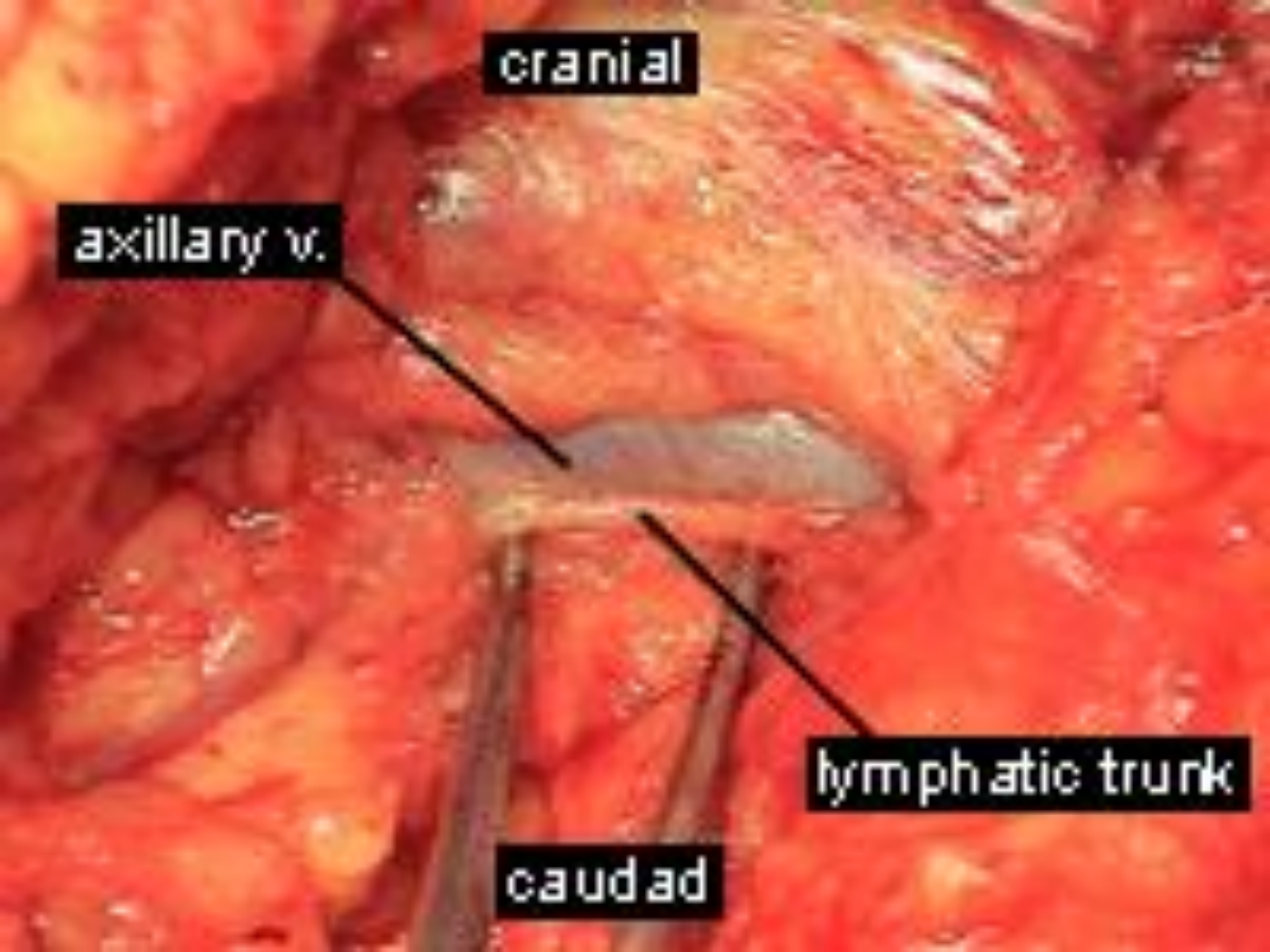
cranial
axillary v.
lymphatic trunk
caudad

Problem

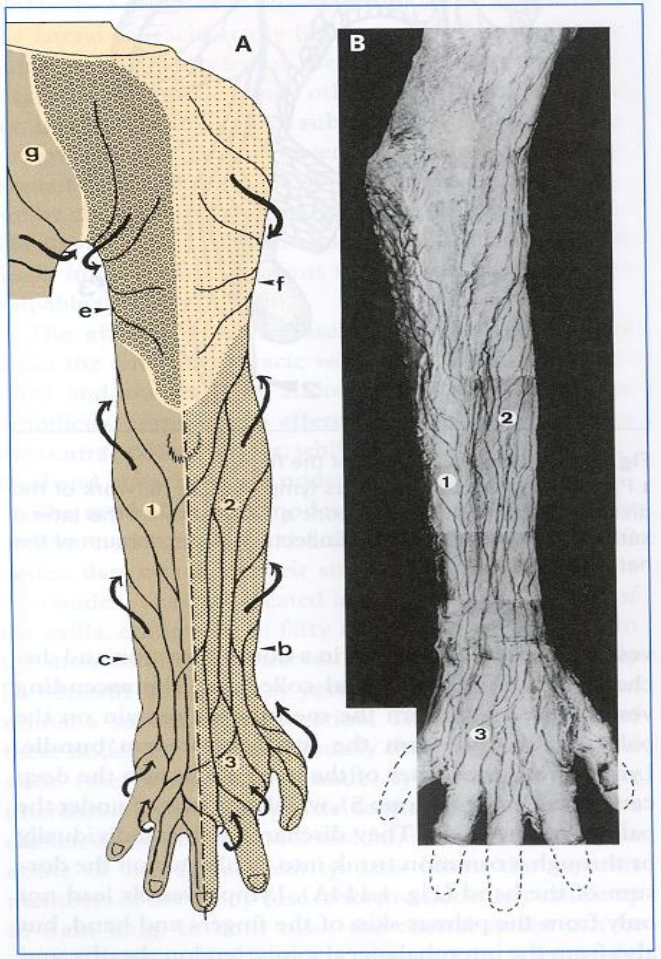

Fig. 1.113 Lymph vessel bundles and lymph territories on the dorsal side of the upper extremity. **A** Schematic diagram of the lymph territories **B** Injection specimen
1 Ulnar bundle **2** Radial bundle **3** Long cross-collateral between radial and ulnar collectors of the dorsum of the hand **b** Territory of the radial bundle **c** Territory of the ulnar bundle **e** Dorsomedial territory of the upper arm **f** Dorsolateral territory of the upper arm territory **g** Upper territory of the trunk [M 124]

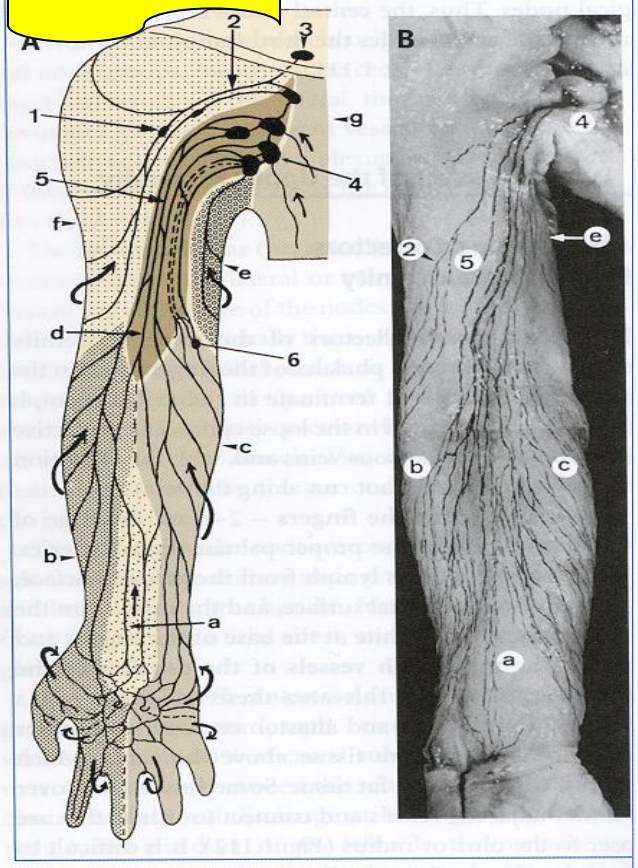

Fig. 1.114 Lymph vessel bundles and lymph territories the upper extremity (palmar view). **A** Schematic diagram the lymph territories with the lymphatic drainage divide that separate them **B** Injection specimen (fetus, 20 c crown-rump length).
a Middle territory of the forearm with median forearm bund **b** Territory of the radial bundle **c** Territory of the ulnar bund **d** Middle territory of the upper arm **e** Dorsomedial territory the upper arm **f** Dorsolateral territory of the upper arm ar shoulder **g** Upper territory of the trunk **1** Deltoideopector l.n.'s **2** Lateral upper arm or deltoid bundle (short typ **3** Supraclavicular l.n. **4** Axillary l.n.'s **5** Median bundle of t upper arm **6** Superficial cubital l.n. [M 124]

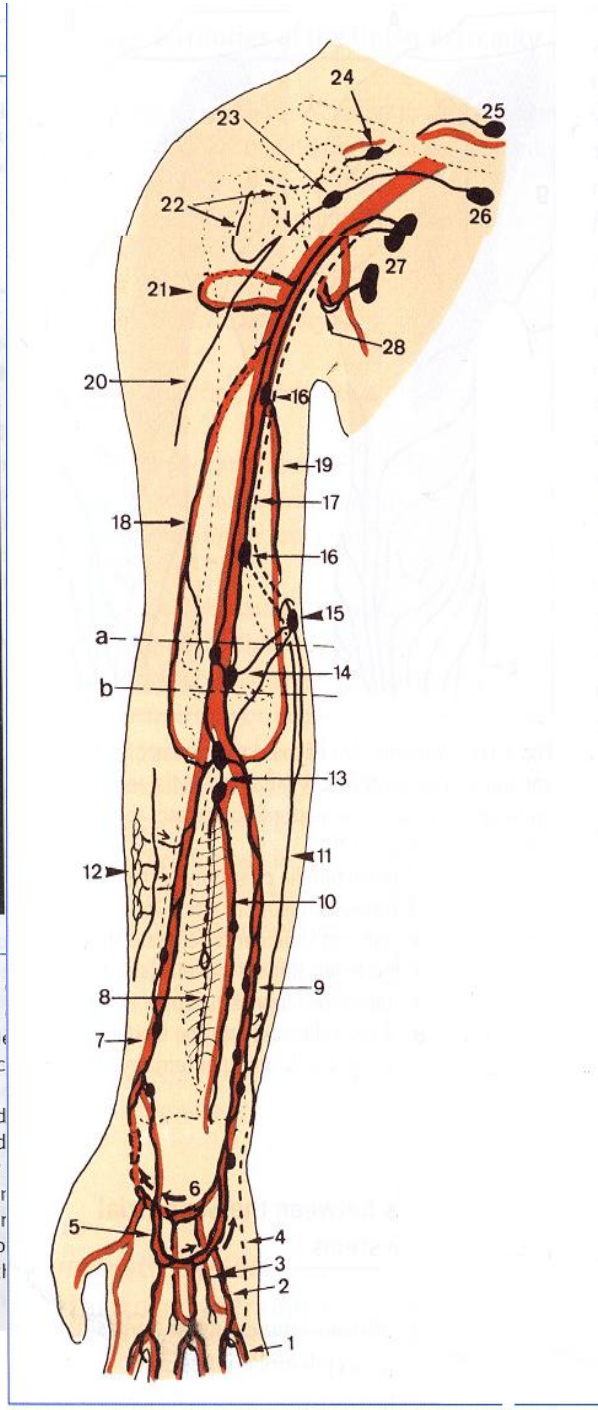

Foldi

Problem

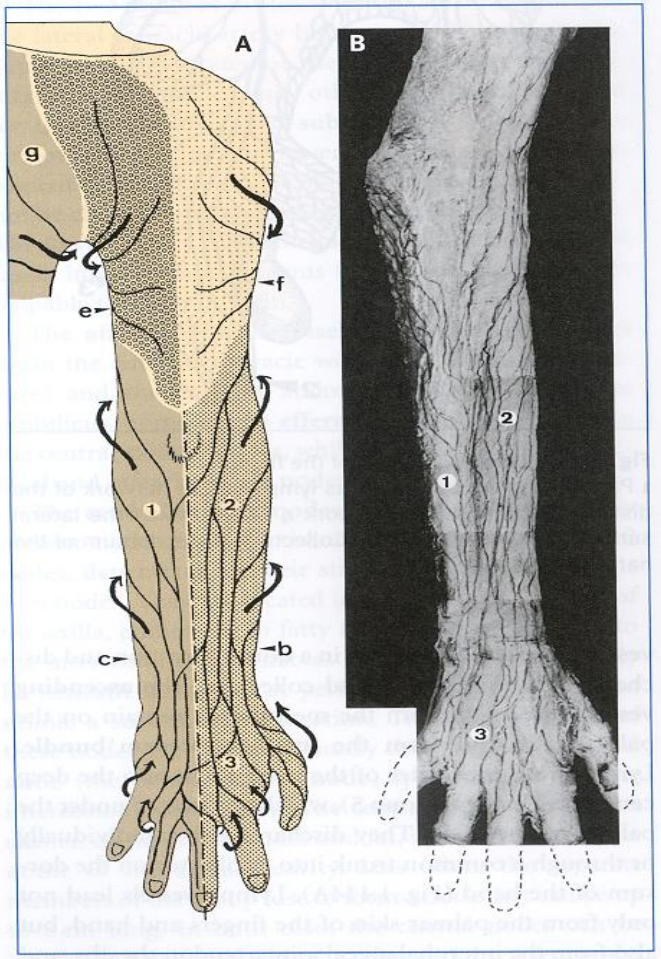

Fig. 1.113 Lymph vessel bundles and lymph territories on the dorsal side of the upper extremity. **A** Schematic diagram of the lymph territories **B** Injection specimen
1 Ulnar bundle **2** Radial bundle **3** Long cross-collateral between radial and ulnar collectors of the dorsum of the hand **b** Territory of the radial bundle **c** Territory of the ulnar bundle **e** Dorsomedial territory of the upper arm **f** Dorsolateral territory of the upper arm territory **g** Upper territory of the trunk [M 124]

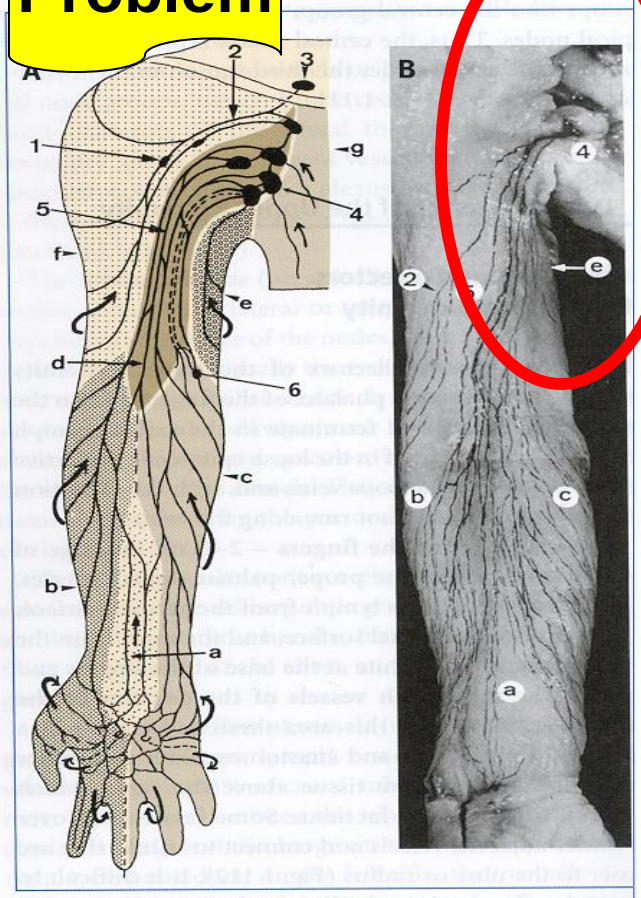

Fig. 1.114 Lymph vessel bundles and lymph territories the upper extremity (palmar view). **A** Schematic diagram the lymph territories with the lymphatic drainage divide that separate them **B** Injection specimen (fetus, 20 c crown-rump length).
a Middle territory of the forearm with median forearm bund **b** Territory of the radial bundle **c** Territory of the ulnar bund **d** Middle territory of the upper arm **e** Dorsomedial territory the upper arm **f** Dorsolateral territory of the upper arm ar shoulder **g** Upper territory of the trunk **1** Deltoideopector l.n.'s **2** Lateral upper arm or deltoid bundle (short typ **3** Supraclavicular l.n. **4** Axillary l.n.'s **5** Median bundle of t upper arm **6** Superficial cubital l.n. [M 124]

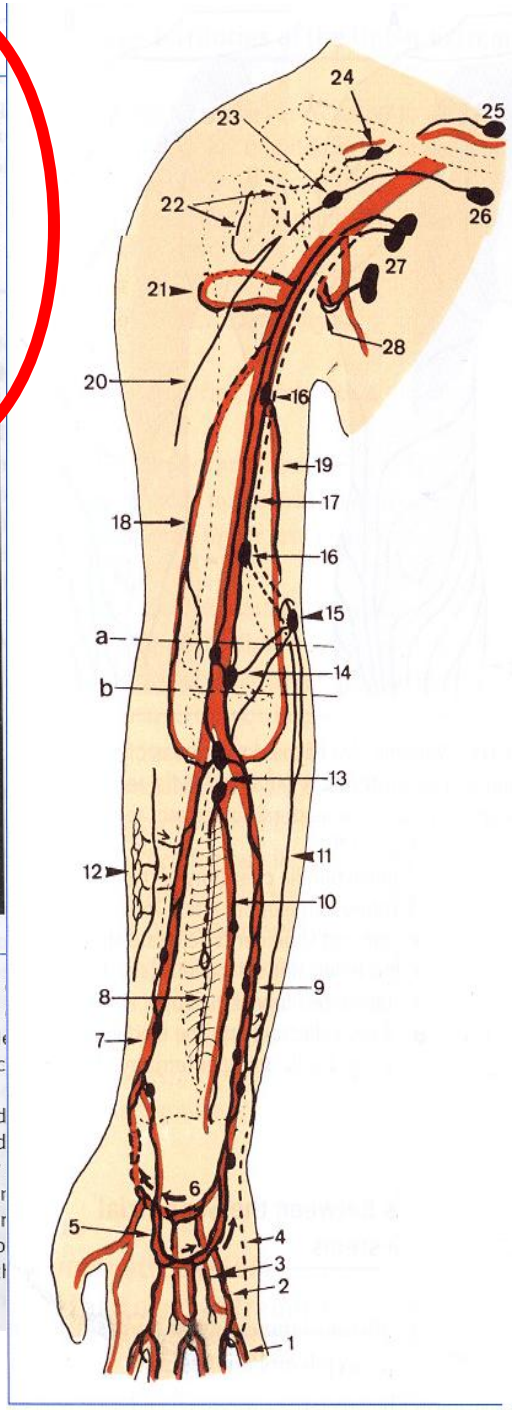

Foldi

Hypothesis

Therefore Mapping the Drainage of the Arm with Blue Dye:

Axillary Reverse Mapping (ARM)

Would ↓ the Likelihood of Disruption of the Arm Lymphatics and Subsequent Lymphedema.

ARM Concept

***AnnSurgOnc 2007*;14(2):84.**

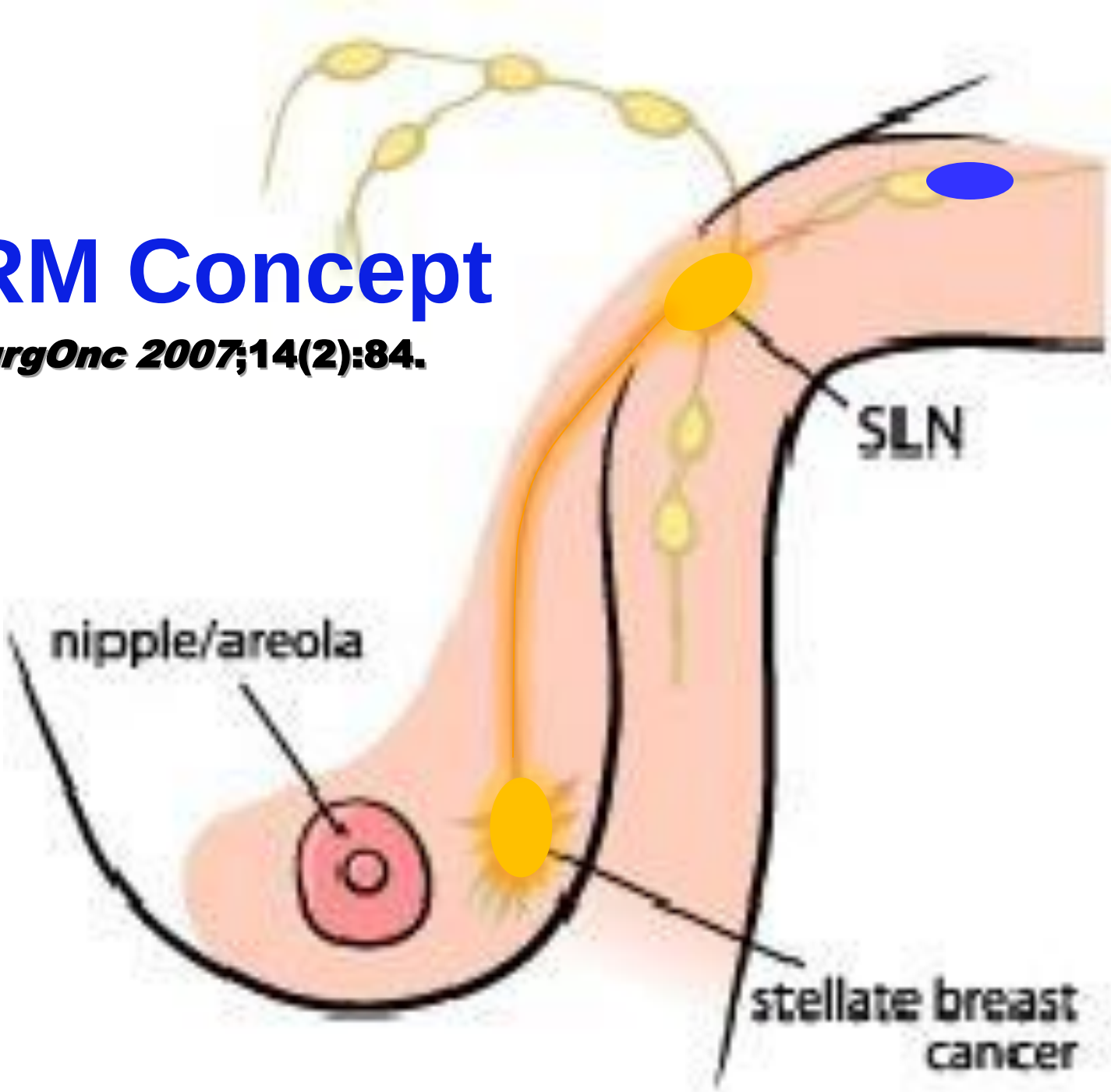

ARM Concept

***AnnSurgOnc 2007*;14(2):84.**

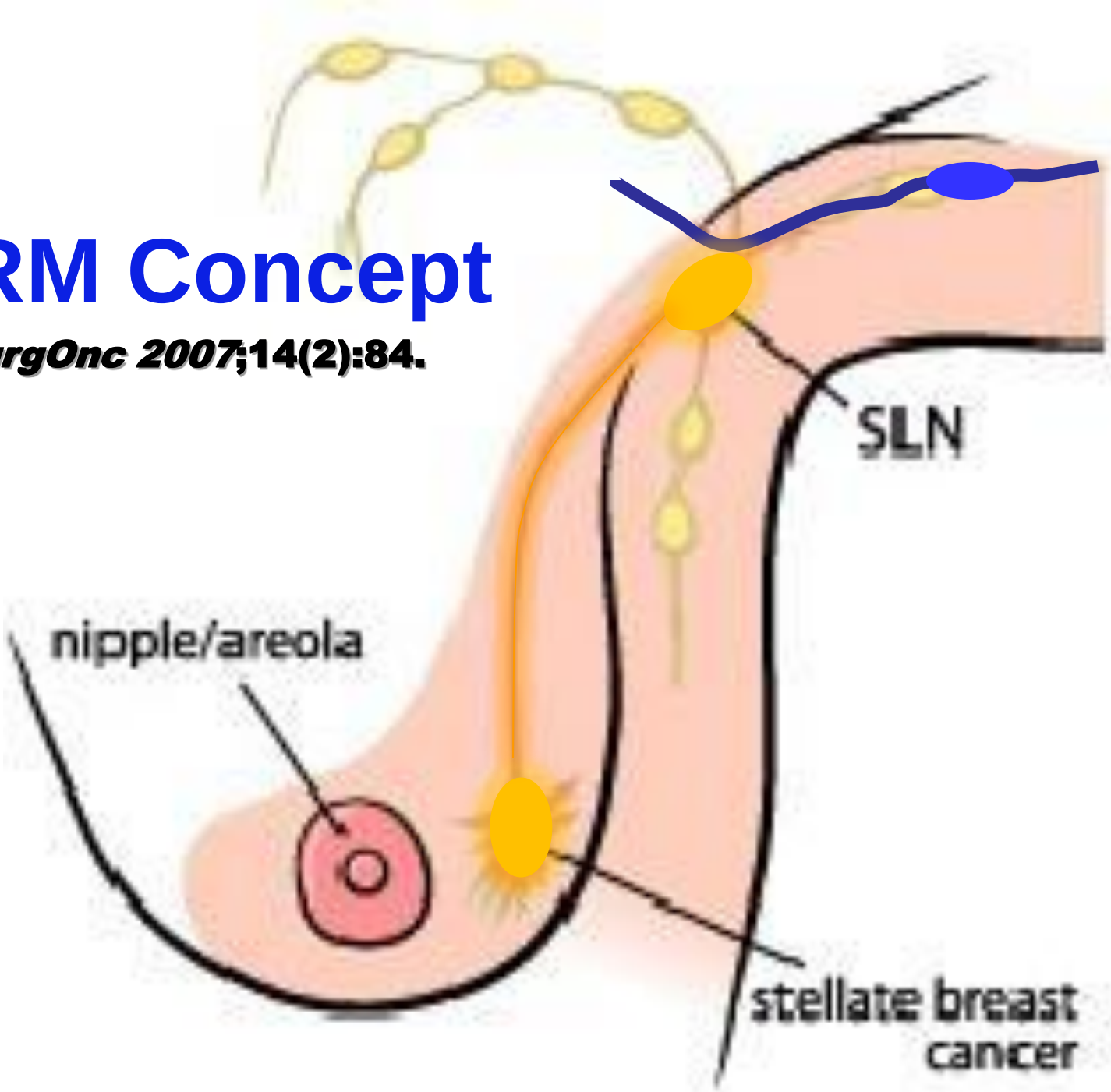

ARM Concept

***AnnSurgOnc 2007*;14(2):84.**

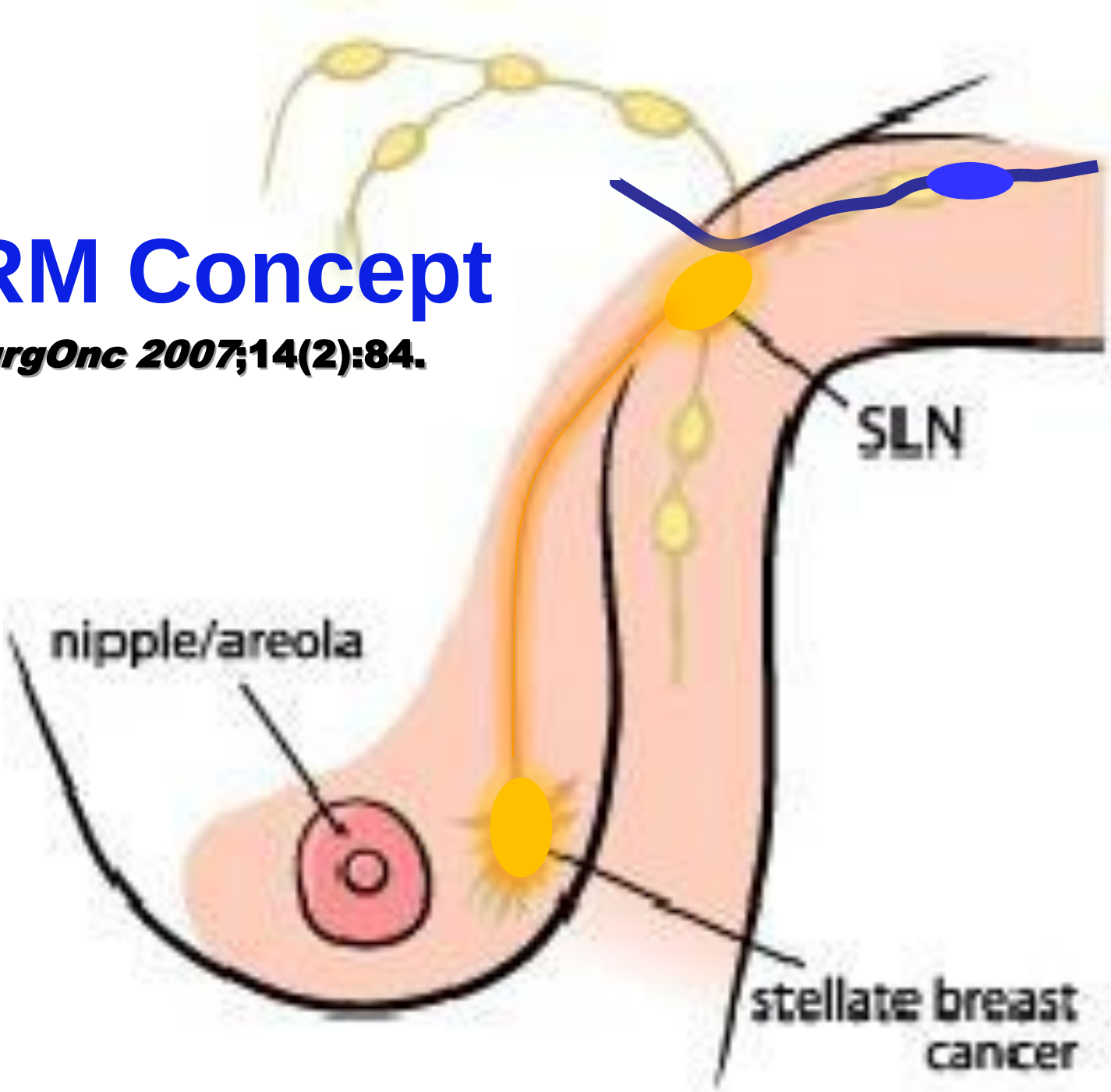

ARM Concept

***AnnSurgOnc 2007*;14(2):84.**

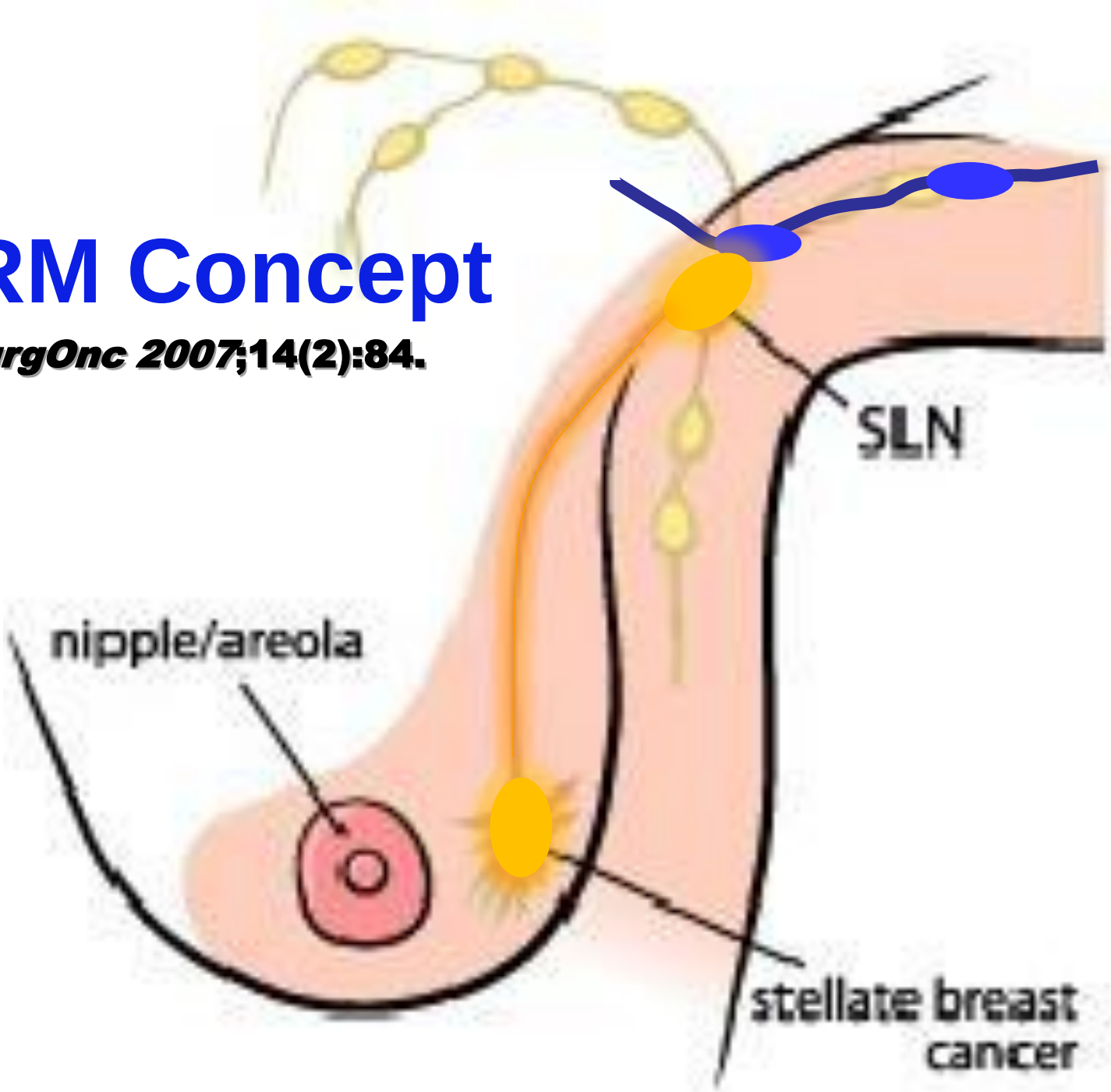

ARM Concept

***AnnSurgOnc 2007*;14(2):84.**

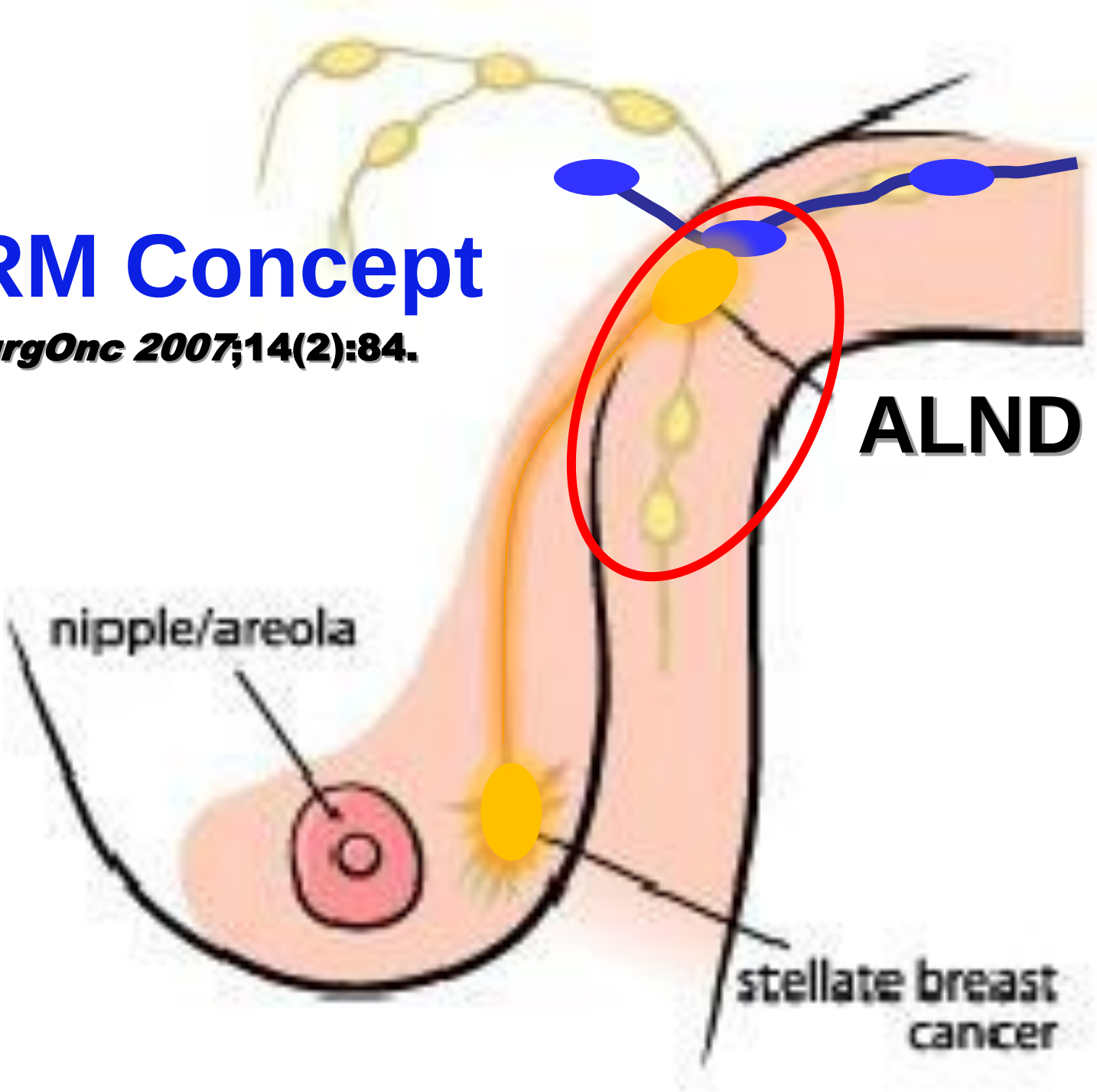

ARM: Axillary Reverse Mapping

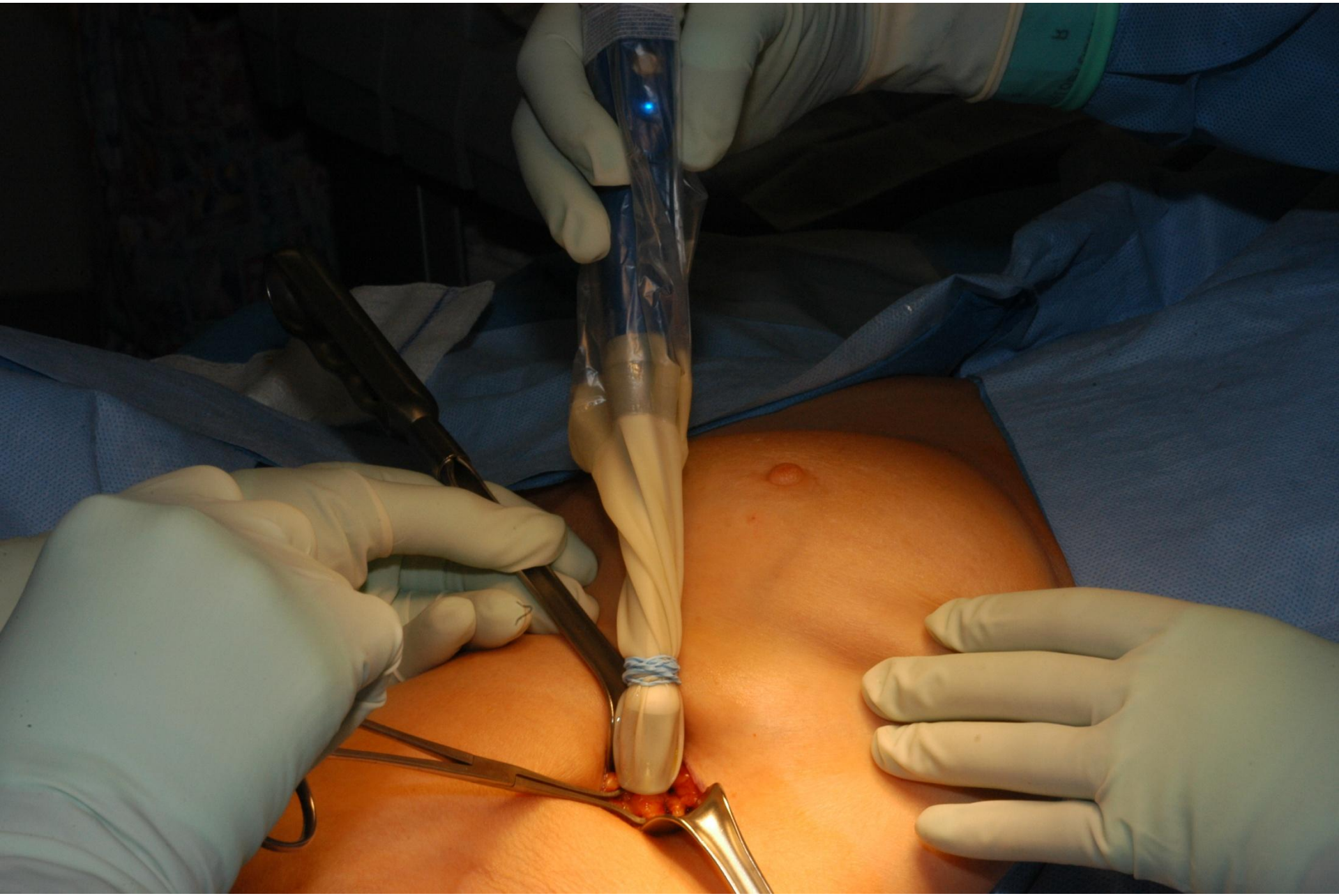

HARMONIC ACE

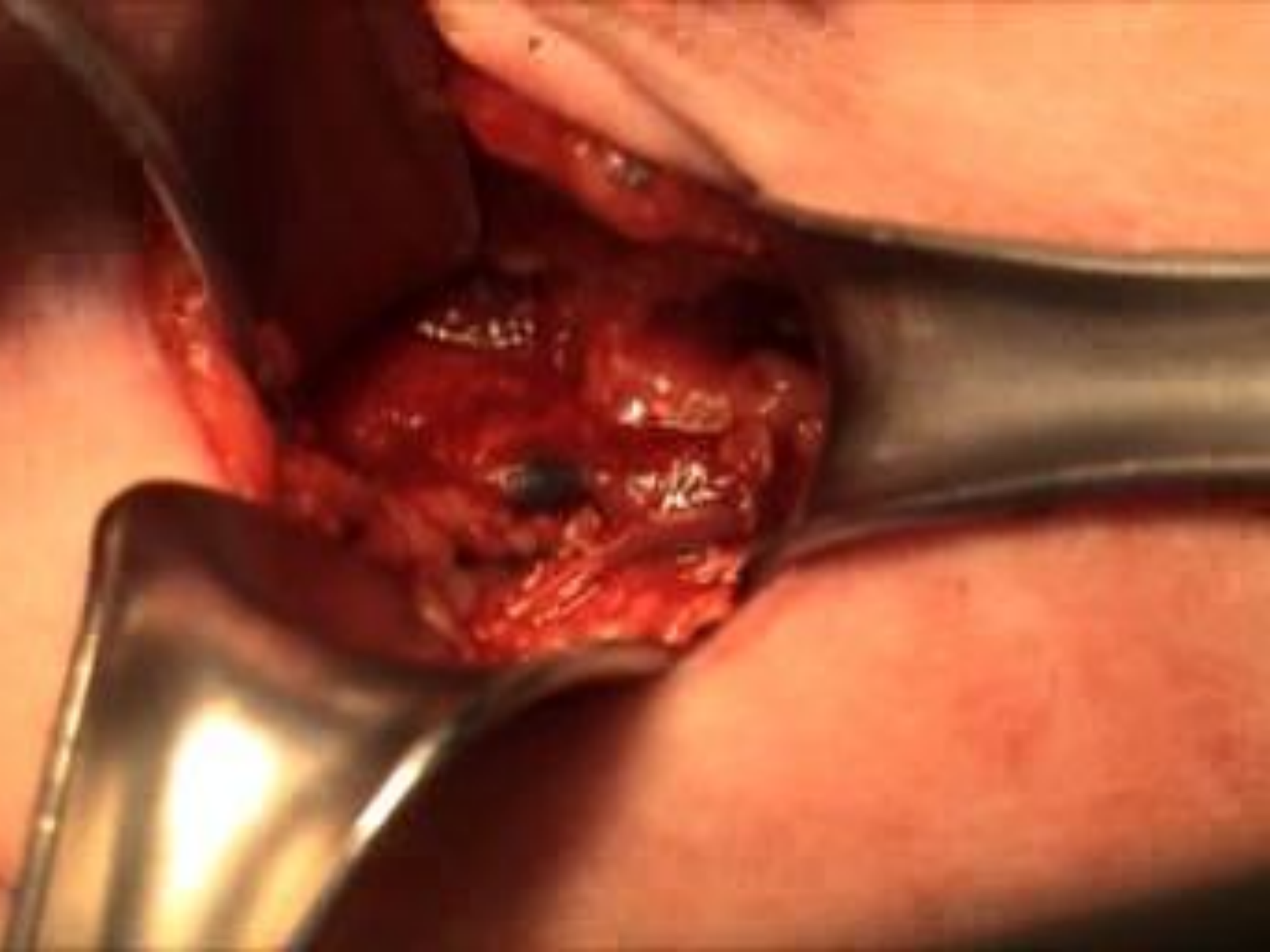

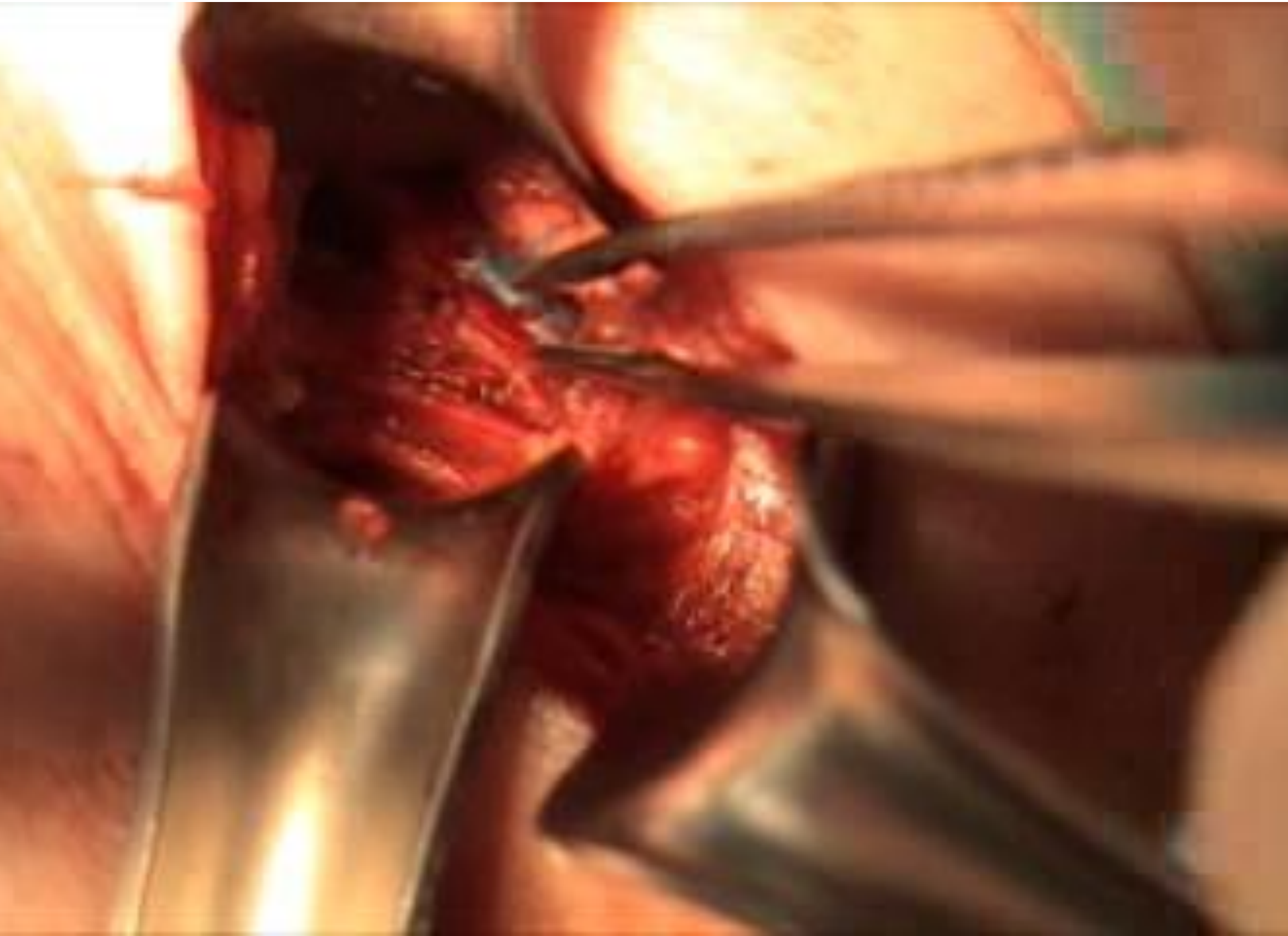

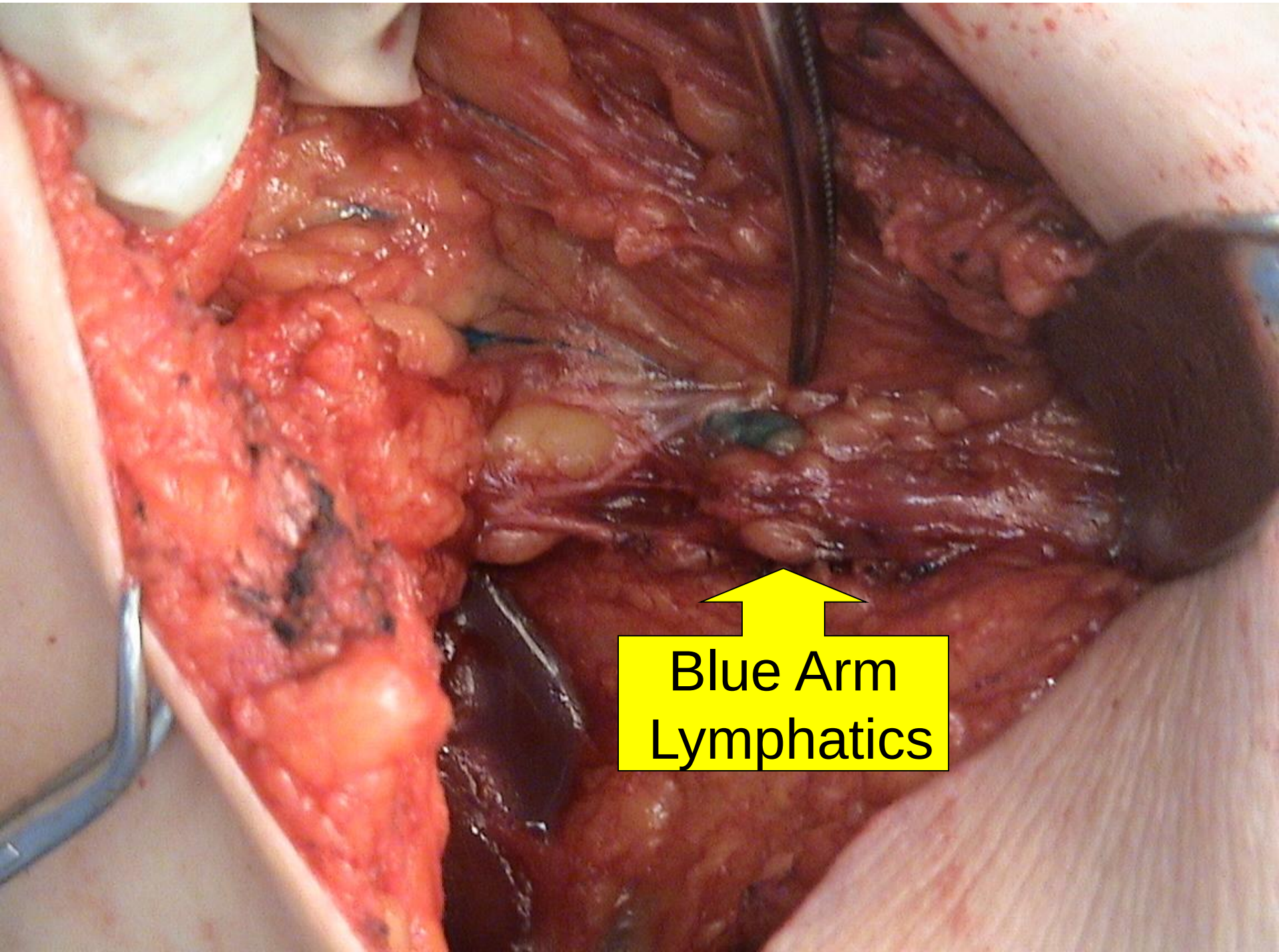
Blue Arm
Lymphatics

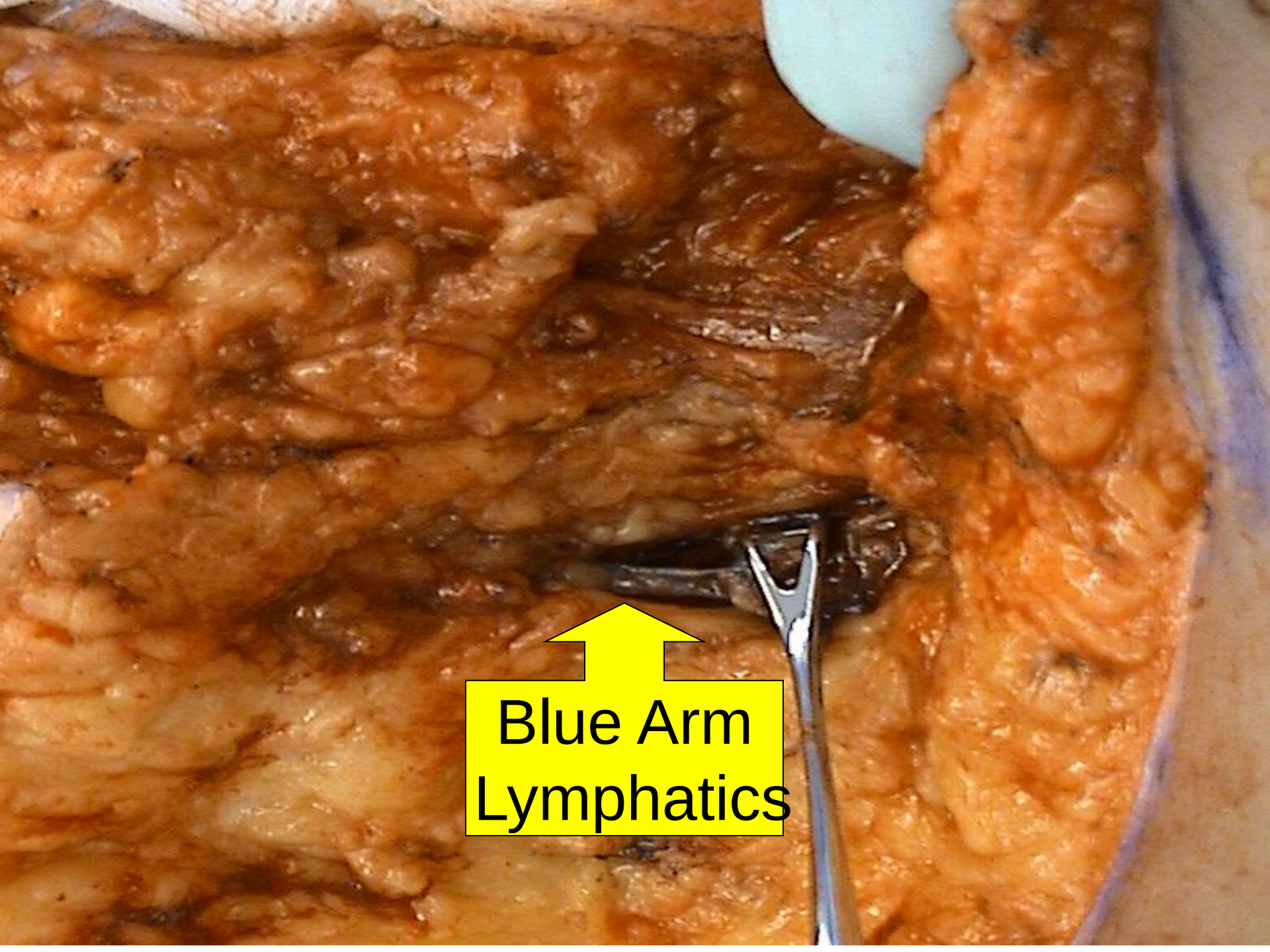
Blue Arm
Lymphatics

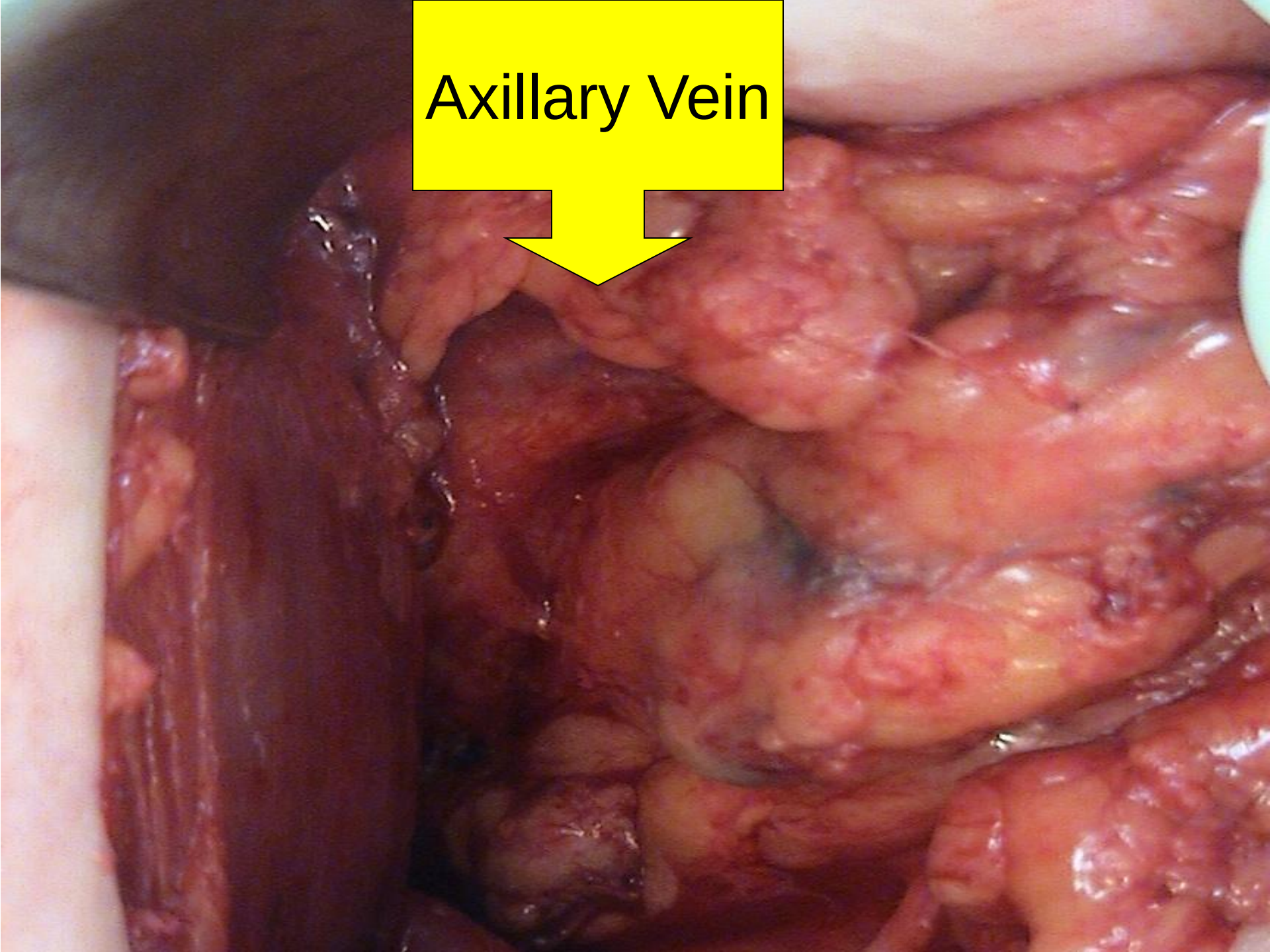
Axillary Vein

Axillary Reverse Mapping (ARM): A New Concept to Identify & Enhance Lymphatic Preservation. *AnnSurgOnc 2007*;14(2):84.

Initial ARM Results

	ID Subareolar Isotope Only	Hot & Blue	
SLNB	60/62 (97%)	0/60 (0%)	

Initial ARM Results

	ARM Blue Lymphatic ID in Axilla	ARM Blue and Hot	ARM + / Axilla+
ALND	18/21 (85%)	0/18 (0%)	0/8

ARM Initial

	Blue Lymphatic Identified in Axilla
Radioactive SLNB Only	22/62 (35%)

Conclusions

- **There was non-concordance of arm & breast lymphatic drainage even in heavily positive axillas.**
- **There were clinically significant lymphatic variations that ARM identified & allowed preservation in all but one case.**
- **ARM added to ALND as well as SLNB further delineates the axilla & may help prevent lymphedema.**

Proposed ARM Study

- Pts Undergoing SLN±ALND
- ARM
- Record Non-Concordance
  - SLN ID Rate & Hot but not Blue
  - ID Rate of Blue ARM Lymphatic & Blue but Not Hot
- In first 5 ALND-Remove Blue Node with ALND
  - Record Percent Blue ARM Nodes that Path+
- Remaining Cases - Determine Ability to
  - ID, Dissect Free and Spare Blue ARM Node
- Record Lymphedema over Time